

# Annals of Translational Medicine

--Manuscript Summary--

Manuscript ID	ATM-18-23
Title	Teeth infection may shunt through Fontan in high-altitude conditions
Running Head	Brain abscess due to dental infection in Fontan Surgery
Keywords	brain abscess,Fontan,single ventricle repair,Streptococcus,bacteremia
Abstract	<p>The Fontan surgery involves the creation a conduit between the inferior vena cava and the right pulmonary artery. This conduit has a small fenestration that shunts the blood from right to left in case the pulmonary blood flow is limited; namely, if the pulmonary vascular resistance is increased then the shunt is increased. Thus bacteria may bypass the pulmonary circulation and easily get access to the systemic circulation (bacteremia). We report the case of a patient that underwent Fontan surgery in 2010 and remained in a high-altitude city for 7 years, during this time he was asymptomatic until 2017 when he developed a brain abscess due to <i>Streptococcus gordonii</i>, a pathogen of dental plaque. Since high-altitude may raise pulmonary vascular resistance in response to reduction in the partial pressure of oxygen, we conclude that the long-term outcome of increased altitude on Fontan hemodynamics can lead to the shunt of teeth flora and lead to severe infections.</p>
Section Title	Case Report

## **Case Report**

### **Teeth infection may “shunt” through Fontan in high-altitude conditions**

#### **Brain abscess due to dental infection in Fontan Surgery**

**Cano Sierra, Juan D\* (Corresponding Author)**

*Pediatric Cardiology Hospitalist, Fundación Cardioinfantil*

*Address: Cl. 163a #13B-60, Bogotá, Colombia*

*E-mail: [csdavid0413@gmail.com](mailto:csdavid0413@gmail.com)*

*Telephone number: +057 318 209 8921*

**Mestra, Camilo F**

*Pediatric Cardiology Department, Universidad del Rosario, Bogotá, Colombia*

*Address: Cl. 12c #6-25, Bogotá*

**Gelvez Nieto, Juan C**

*Pediatrics Department, Universidad del Rosario, Bogotá Colombia*

*Address: Cl. 12c #6-25, Bogotá*

**Ronderos Dumit, Miguel**

*(Pediatric Interventional Cardiology Department, Fundación Cardioinfantil, Bogotá, Colombia)*

*Address: Cl. 163a #13B-60, Bogotá, Colombia*

**Garcia Torres, Alberto**

*(Pediatric Interventional Cardiology Department, Fundación Cardioinfantil, Bogotá, Colombia)*

*Address: Cl. 163a #13B-60, Bogotá, Colombia*

**Total Number of Figures:** 3

**Source of Support:** None

**Acknowledgement:** The authors thank all the medical staff involved in patient care

**Conflict of Interest:** None

## Teeth infection may “shunt” through Fontan in high-altitude conditions

### Brain abscess due to dental infection in Fontan Surgery

#### Abstract

The Fontan surgery involves the creation a conduit between the inferior vena cava and the right pulmonary artery. This conduit has a small fenestration that shunts the blood from right to left in case the pulmonary blood flow is limited; namely, if the pulmonary vascular resistance is increased then the shunt is increased. Thus bacteria may bypass the pulmonary circulation and easily get access to the systemic circulation (bacteremia). We report the case of a patient that underwent Fontan surgery in 2010 and remained in a high-altitude city for 7 years, during this time he was asymptomatic until 2017 when he developed a brain abscess due to *Streptococcus gordonii*, a pathogen of dental plaque. Since high-altitude may raise pulmonary vascular resistance in response to reduction in the partial pressure of oxygen, we conclude that the long-term outcome of increased altitude on Fontan hemodynamics can lead to the shunt of teeth flora and lead to severe infections.

**Keywords:** brain abscess, Fontan, single ventricle repair, Streptococcus, bacteremia

## Introduction

The Fontan surgery is the last staged operation for children with congenital heart disease who are not candidates for a 2-ventricle repair (1). When this procedure is made at a higher elevation city, the chronic alveolar hypoxia increases pulmonary vascular resistance (PVR) leading to an increase in the right to left shunt (2). The success of this operation depends in large part on this resistance, and it is described that any factor that increases PVR will ultimately lead to a negative impact on Fontan hemodynamics (3) and finally to a steep rise in long-term complications.

The Fontan surgery involves the creation a conduit between the inferior vena cava and the right pulmonary artery. This conduit has a small fenestration that shunts the blood from the Fontan to the right atrium in case the pulmonary blood flow is limited increasing the preload of the systemic ventricle, at the expense of lowering the systemic oxygenation and the risks that involves the right to left shunt (i.e., embolism, systemic infection) (4).

Theoretically an increase in PVR associated with high altitude will increase the shunt through the Fontan fenestration to the right atrium and then to the systemic ventricle. Normal brushing of teeth increases the number of bacteria in the bloodstream and theoretically they can bypass the pulmonary circulation and get access to the systemic circulation leading to severe infections. In the literature there are many described complications of the Fontan, however, there is no description of teeth infection shunting to the brain when the patients are exposed to high altitude for a long term (5). We report a case of a patient with brain abscess associated with *Streptococcus gordonii*, bacteria of the normal flora of the teeth and dental plaque.

## Case report

An 11-year old patient living in a high-altitude city in Colombia; previously known in our institution with a history of tricuspid atresia with normally related great arteries with large ventricular septal defect without pulmonary stenosis, who had undergone a fenestrated extracardiac Fontan surgery in 2010. In 2017 he presented to the emergency department with a 2-week history of headache, vomiting and fever. The parents emphasized that the patient was not the same and that during the day he developed short episodes of

depersonalization and disorientation, he was on furosemide 20 mg/day, spironolactone 25 mg/day and warfarin 5 mg/day. On physical examination, he had two of the classic Cushing triad; his blood pressure was 128/85 (over 99<sup>th</sup> percentile for age), heart rate was 38 beats/min, respiratory rate was normal at 18 breaths/min, oxygen saturation was 75% while breathing ambient air, and body temperature was 36.5°C. He was alert, oriented and had no signs of neurological deficit and dental exam revealed two dental cavities in molar teeth and signs of dental caries. Owing to the risk of bleeding (i.e. anticoagulation) and the neurological symptoms referred by the parents, the patient was admitted for further studies.

The complete blood count (CBC) revealed a white blood cell count of 13800/ $\mu$ L with left deviation (84.5% of neutrophils). The C-reactive protein level was 1.11 mg/dl and the erythrocyte sedimentation rate was 2 mm/h, the international normalized ratio (INR) was 1.35. The echocardiogram revealed a dilated left ventricle with a mild decrease in ejection fraction of 55% with right to left shunt from the extracardiac Fontan to the right atrium through the fenestration without evidence of intracardiac infection (i.e. abscess) or vegetations (**Figs. Ia, b**). Computed tomography (CT) scan showed a large mass over the occipital and parietal lobe with left ventricle compression and left midline shift (**Figs. IIa, b, c**). With the suspicion of a pyogenic abscess versus parenchymal hemorrhage, we covered the patient with vancomycin and cefepime and discontinued anticoagulation. Considering the risk of neurological deterioration, we took the patient to surgery.

Under general anesthesia; a right occipital and parietal incision was made and a craniotomy was performed with high speed CRANIO-Blade; an approximate of 40 ml intra-axial liquid mass with profuse exudate was drained; unfortunately, the bone could not be marsupialized due to the extended infection.

The pus was sent to the microbiology laboratory for culture. A blood agar at 37°C in ambient air, showed the growth of small non-hemolytic colonies after 72 hours of incubation. The isolation was identified as *Streptococcus gordonii* with the Microgen ® Strep ID Panel. Antimicrobial susceptibility was done with the modified Kirby-Bauer test, the microorganism minimum inhibitory concentrations were > 8 for erythromycin (Resistant), 0.06 for penicillin (Intermediate) and 2 for Ceftriaxone (Intermediate).

A repeated CT scan (**Fig. IIId**) was performed after the surgery. It showed a significant reduction in the midline shift and compression of left ventricle. The patient blood cultures were negative at 7 days of incubation. After the isolate the antibiotic treatment was de-escalated to Vancomycin 400 mg intravenous (IV) every 6 hours for 42 days. The levels of Vancomycin remained at 19.43 µg/ml and the clinical response was excellent. The patient underwent molar extraction and dental capping of compromised teeth.

## Discussion

Brain abscess is a serious and life-threatening clinical entity, this infection is the result of spread from a contiguous focus of infection like hematogenous seeding from a distant source (6). The diagnosis of brain abscess is considered definite if bacterial organisms are isolated from abscess pus or cerebral spinal fluid cultures. The isolated organisms vary with underlying medical or surgical conditions. In this case confirmation of abscess has come about upon CT scan findings characteristic of brain abscess and bacterial growth from the pus culture.

The *Streptococcus viridans* group readily colonizes the dental plaque and it has been described as a potential etiology of brain abscess. This group is composed of several species, and particularly the *S. anginosus* group species are usually isolated from brain abscesses (7). In our case we reported *Streptococcus gordonii* as the isolate; to date, it has not been described in brain abscess in the context of Congenital Heart Disease. This specie has the same potential to colonize the dental plaque as *Streptococcus sanguinis* (8). Other *viridans* group bacteria isolated from brain abscesses had been described due to *Streptococcus oralis* in patients with Congenital Heart Disease (9); increasing the importance of dental care in patients with right to left shunt diseases.

Our theory is that the patient was infected in the dental cavities with *Streptococcus gordonii*, and probably tooth brushing or dental procedures disrupted the surface of gingival tissue and caused bacteremia (10). All these bacteria bypassed through the Fontan fenestration to the right atrium and then to the systemic circulation. Although it has been reported that immunosuppressed patients are the population at risk of having

*Streptococcus viridans* brain abscess (11), we assume that in the context of congenital heart disease with Fontan palliation the regular seeding of bacteria in the brain can lead to chronic infections (Fig III).

Unique physiological changes caused by Fontan circulation include a single-ventricle circulation, passive venous flow to the lungs instead of the normal pulsatile lung perfusion, systemic venous hypertension, and scarring in the heart. (12). Thus, there is a concern about the negative impact that chronic teeth infection and altitude may have on the outcome of the Fontan procedure. Since low pulmonary vascular resistance is a major criterion for the successful creation of a Fontan circulation and high-altitude may rise PVR in response to reduction in the partial pressure of oxygen (3) we conclude that dental infections associated with increased altitude altered Fontan hemodynamics can lead to severe infections. We ought to provide the patients the recommendation of living in low altitude cities and keep an excellent dental hygiene.



### Figure Legends

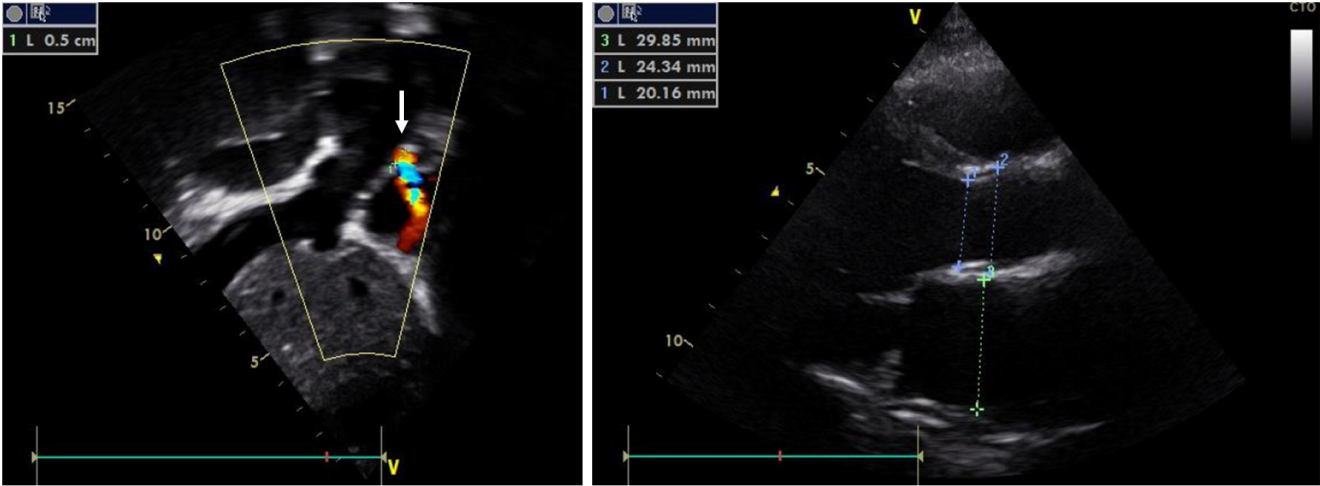
**FIGURE 1. Transthoracic echocardiogram.** A Sub-external axis showing right to left shunt from the Fontan fenestration (0.5 cm) to the right atrium (white arrow) B. Long sternal axis showing left ventricle dilatation without evidence of infective endocarditis.

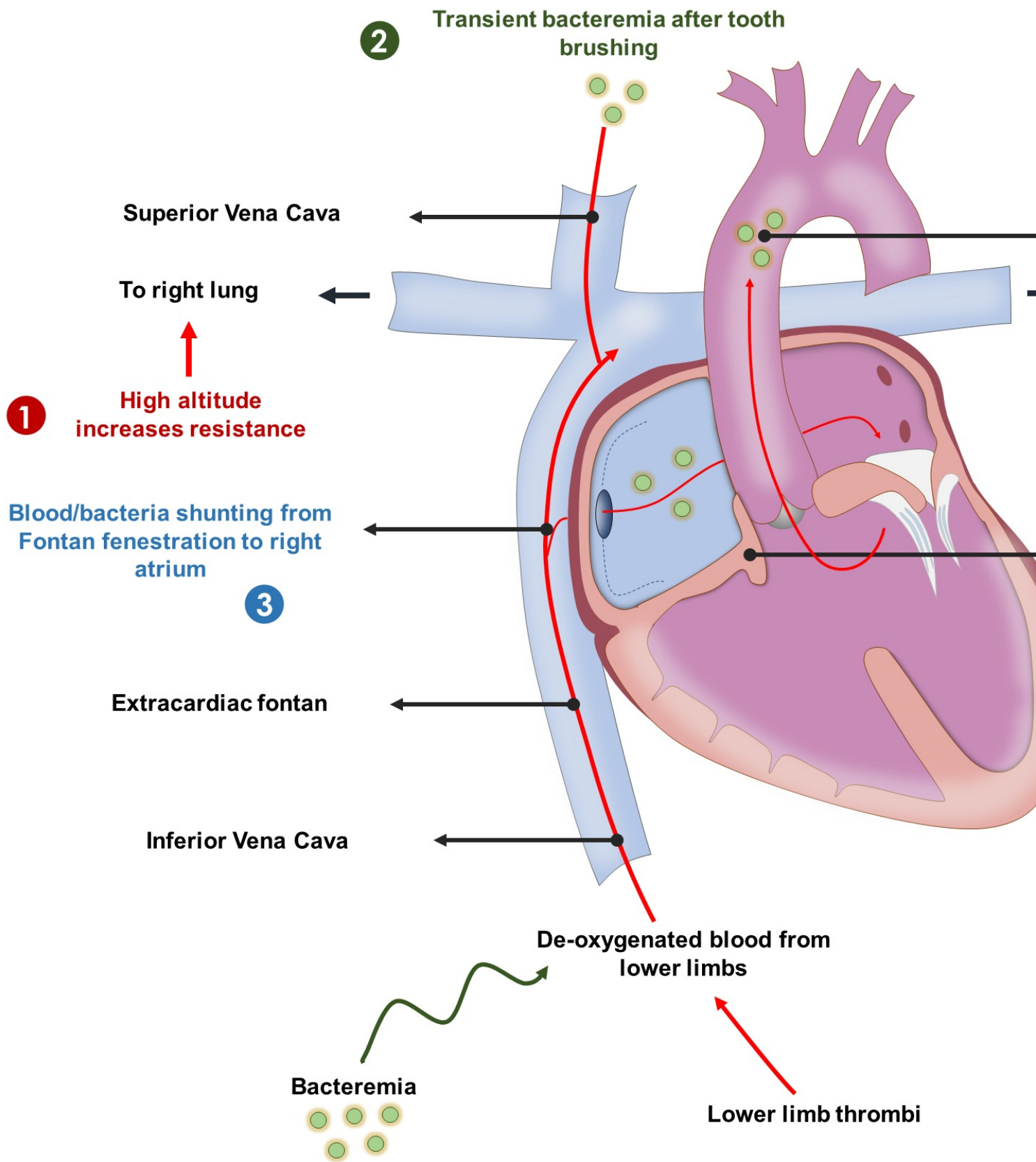
**FIGURE 2. Computed tomography (CT) scan showing the brain abscess.** A, axial cut showing a large mass over the occipital and parietal lobe with left ventricle compression and left midline shift. B, Coronal cut. C, Sagittal cut. D, decrease of the mass after surgery.

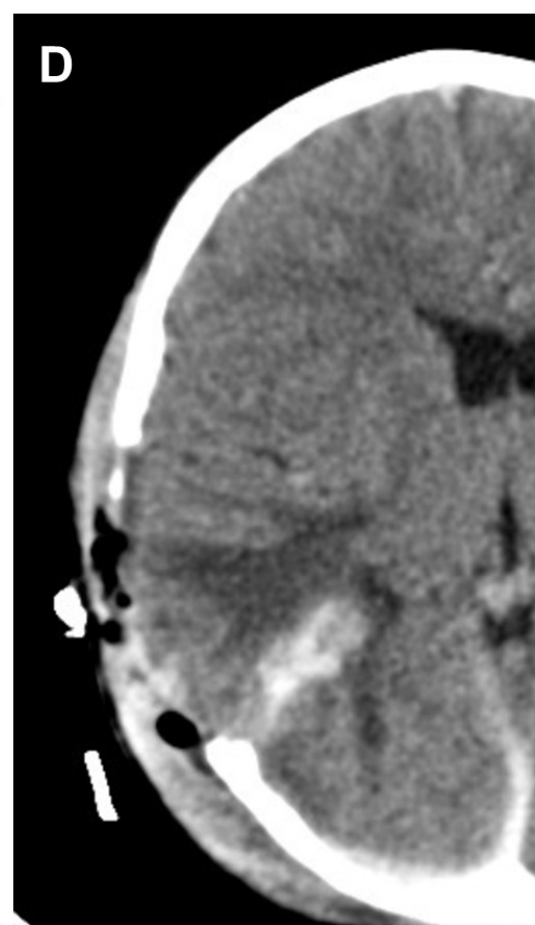
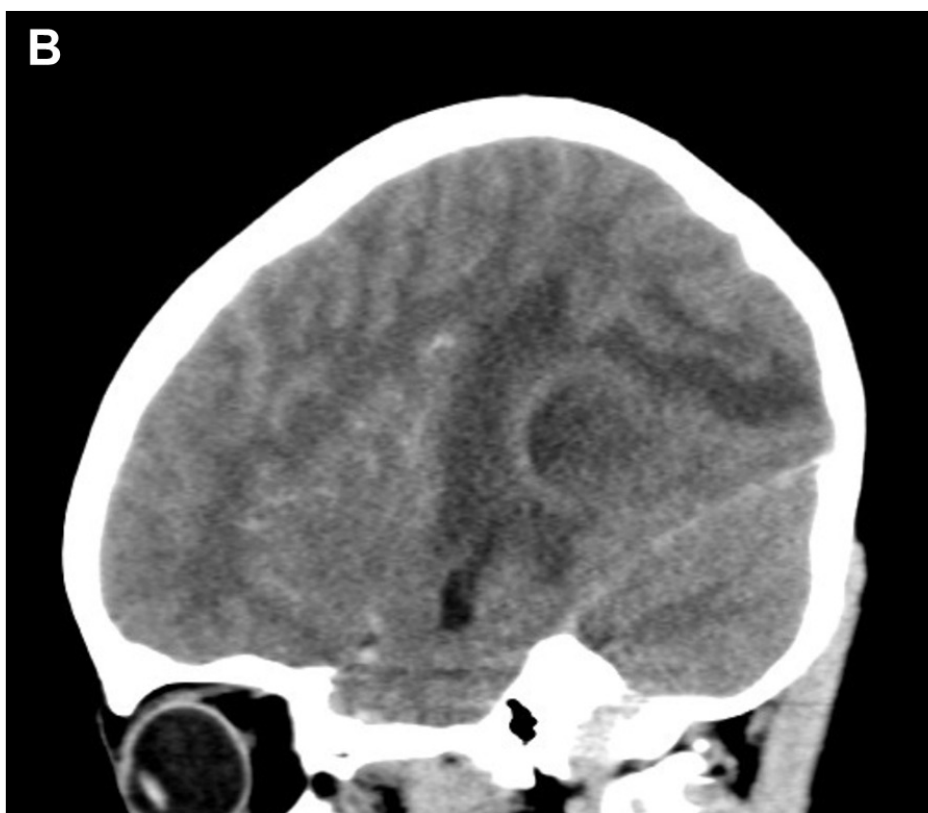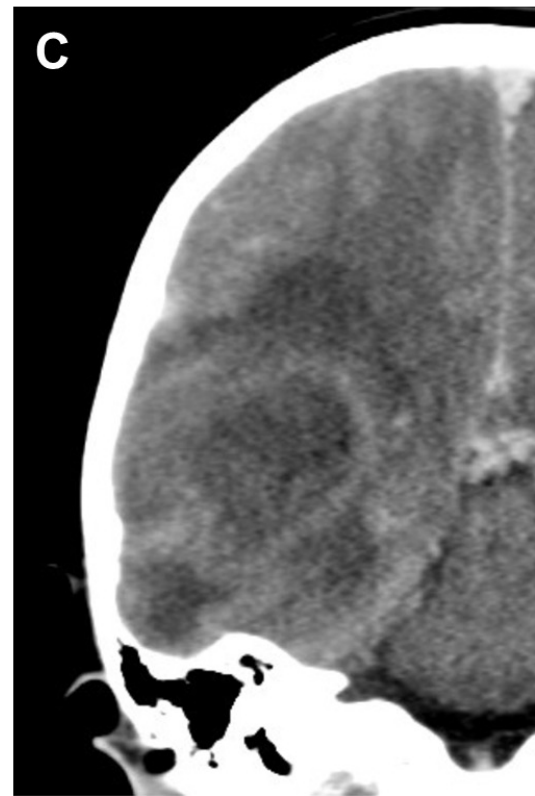
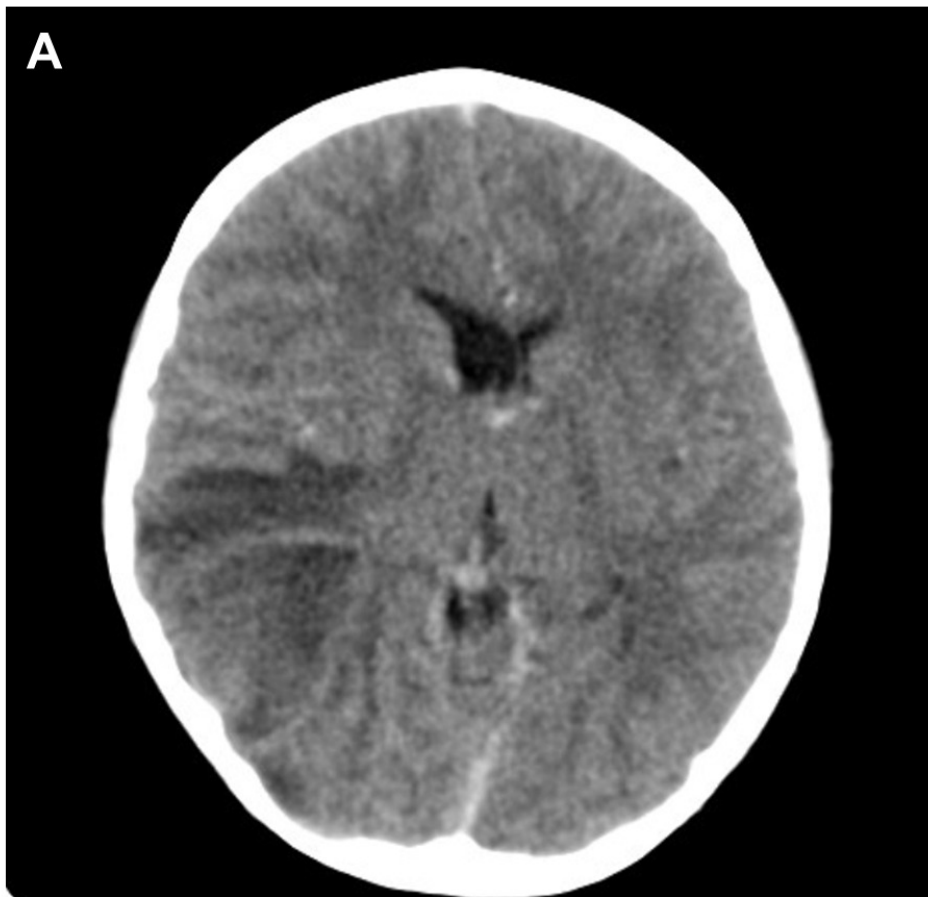
**FIGURE 3. Proposed sequential events that lead to shunting of teeth infections when there is compromised Fontan hemodynamics at high altitude.** (1) An increase in altitude leads to an increase in pulmonary resistance then the shunt from the Fontan to the right atrium is increased. (2) Bacteremia from distant infections, from dental brushing or even lower limb thrombi can bypass pulmonary filter through (3) Fontan fenestration. (4) Finally bacteria are pumped to the systemic circulation increasing the risk of fatal infections.

## References

1. D'Udekem Y, Iyengar AJ, Cochrane AD, Grigg LE, Ramsay JM, Wheaton GR, et al. The Fontan procedure: Contemporary techniques have improved long-term outcomes. *Circulation*. 2007;116(11 SUPPL. 1).
2. Day RW, Orsmond GS, Sturtevant JE, Hawkins JA, Doty DB, McGough EC. Early and intermediate results of the Fontan procedure at moderately high altitude. *Ann Thorac Surg* [Internet]. The Society of Thoracic Surgeons; 1994;57(1):170–6. Available from: [http://dx.doi.org/10.1016/0003-4975\(94\)90388-3](http://dx.doi.org/10.1016/0003-4975(94)90388-3)
3. Johnson JT, Lindsay I, Day RW, Van Dorn CS, Hoffman J, Everitt MD, et al. Living at altitude adversely affects survival among patients with a fontan procedure. *J Am Coll Cardiol* [Internet]. Elsevier Inc.; 2013;61(12):1283–9. Available from: <http://dx.doi.org/10.1016/j.jacc.2013.01.008>
4. Lemler MS. Fenestration Improves Clinical Outcome of the Fontan Procedure: A Prospective, Randomized Study. *Circulation* [Internet]. 2002;105(2):207–12. Available from: <http://circ.ahajournals.org/content/105/2/207.long>
5. Mehrotra A, Khanna P, Kumar S, Abraham G. Renal abscess after the Fontan procedure: a case report. *J Med Case Rep* [Internet]. 2011;5:50. Available from: <http://www.pubmedcentral.nih.gov/articlerender.fcgi?artid=3048475&tool=pmcentrez&rendertype=abstract>
6. Patel K, Clifford DB. Bacterial Brain Abscess. *The Neurohospitalist* [Internet]. 2014;4(4):196–204. Available from: <http://journals.sagepub.com/doi/10.1177/1941874414540684>
7. Doern CD, Burnham CAD. It's not easy being green: The viridans group streptococci, with a focus on pediatric clinical manifestations. *J Clin Microbiol*. 2010;48(11):3829–35.
8. Zheng W, Tan MF, Old LA, Paterson IC, Jakubovics NS, Choo SW. Distinct Biological Potential of *Streptococcus gordonii* and *Streptococcus sanguinis* Revealed by Comparative Genome Analysis. *Sci Rep* [Internet]. Springer US; 2017;7(1):2949. Available from: <http://www.nature.com/articles/s41598-017-02399-4>
9. Lakshmi V, Bhushanam V, Kumar A, Solanki R, Subramanian S. Brain abscess due to *Streptococcus oralis* in an immunocompetent patient. *Indian J Med Microbiol* [Internet]. 2014;32(2):179. Available from: <http://www.ijmm.org/text.asp?2014/32/2/179/129817>
10. Lockhart PB, Brennan MT, Sasser HC, Philip C, Paster BJ, Bahrani-mougeot FK. NIH Public Access. 2009;117(24):3118–25.
11. Vidal JE, Tuon FF. Brain abscess due to viridans streptococci in a severely immunosuppressed HIV-infected patient. *Int J STD AIDS*. 2009;20:654–6.
12. McRae ME. Long-term Issues After the Fontan Procedure. *AACN Adv Crit Care* [Internet]. 2013;24(3):264–82. Available from: <http://acc.aacnjournals.org/cgi/doi/10.1097/NCI.0b013e31829744c7>







**Compliance with Ethical Standards:**

**Funding:** This study was not funded by any organization and/or institution

**Conflict of Interest:** The authors declare no conflicts of interest

**Ethical approval:** This article does not contain any studies with human participants performed by any of the authors.

**Informed consent:** Informed consent was obtained from the mother of the patient included in the study. We provide a copy of this consent in Spanish.

**CONSENTIMIENTO INFORMADO PARA USO DE DATOS, FOTOGRAFÍAS E IMÁGENES CLÍNICAS  
PARA REPORTE DE CASO**

Bogotá D.C, Colombia. Día ( 4 ) Mes ( 10 ) Año ( 17 )

Por medio de la presente, declaro que el Doctor Juan David Cano S., identificado con Cédula de Ciudadanía No. 1620780489 expedida en Bogotá; ha informado a Diana M. Bernal G. identificado con Cédula de Ciudadanía No. 35374326 expedida en Mosquera sobre su intención de divulgar y hacer público el caso clínico correspondiente a:

Mi persona ( )

Mi hijo ( )  
Nombre Andrés Felipe Díaz Bernal  
Identificado con T.I. 1073232378 No. \_\_\_\_\_

Otro familiar ( )  
Nombre \_\_\_\_\_  
Identificado con \_\_\_\_\_ No. \_\_\_\_\_

Con propósitos puramente académicos y científicos, haciendo uso de la información que de forma verídica le he referido, exámenes de laboratorio y demás estudios que él ha considerado pertinentes. Del mismo modo solicita mi permiso para tomar fotografías clínicas que serán utilizadas de manera profesional. Manifiesto que he sido informado que esta información podrá ayudar a personas que padezcan mi misma condición médica, que mi identidad no será revelada y que siempre se velará por que mi privacidad y anonimato se mantengan en todo momento.

Por lo anterior, autorizo al Doctor Juan David Cano S. la reproducción de la información antes mencionada y el uso de las fotografías que ha tomado bajo mi autorización.

Juan David Cano S.  
Médico que solicita la autorización

Diana Milena Bernal  
Paciente o Representante Legal

Alexandra C. Varela  
Testigo No. 1  
Cédula de Ciudadanía No. 1072103752

Andrés J. Jarama  
Testigo No. 2  
Cédula de Ciudadanía No. 52767105