



**Universidad del  
Rosario**

**The usefulness of cholangioscopy in the diagnosis of peribiliary cysts: case report.**

Autor

**Juan Pablo Valencia Quivano**

Directores

**Dr Geovanny Hernández Cely**

**Dra. Danna Lesley Cruz Rojas**

**Trabajo presentado como requisito para optar por el título de  
Especialista en gastroenterología y endoscopia digestiva**

**Escuela de medicina y ciencias de la salud**

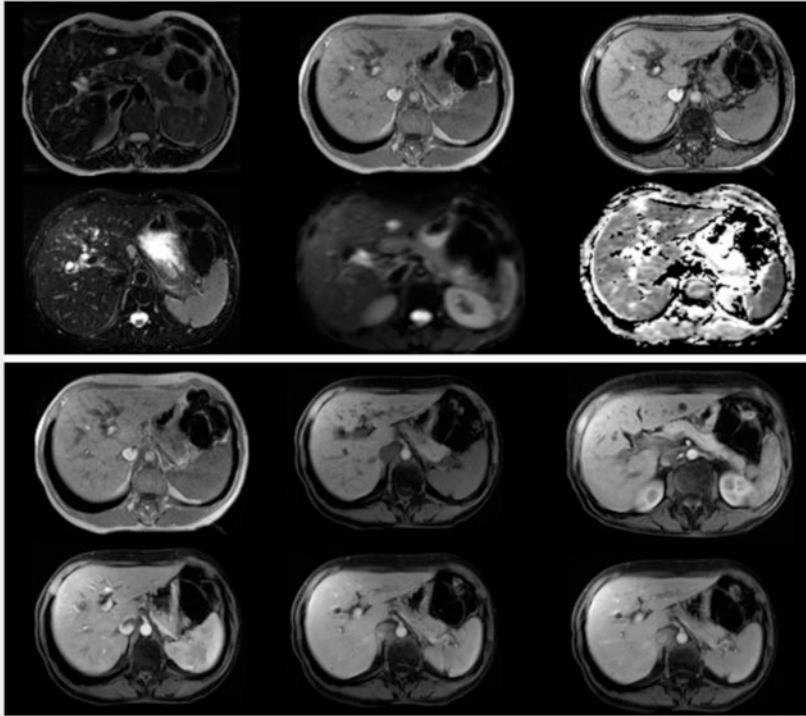
**Especialización en gastroenterología y endoscopia digestiva**

**Universidad del Rosario**

**Bogotá - Colombia**

**2025**

## The usefulness of cholangioscopy in the diagnosis of peribiliary cysts: a case report



► **Fig. 1** Dilatation of the choledochus with an image that could correspond to calculus (only visualized in a sequence). However, there is an abrupt termination of the choledochus and saccular dilations of the intrahepatic biliary tract, so it is not possible to rule out periampullary lesions. Endoscopic evaluation is suggested. The small cystic lesion of the body of the pancreatic head could correspond to intraductal papillary mucinous intraductal neoplasm with no ominous signs. Cysts are simple hepatic cysts.

A 63-year-old woman with no medical or surgical history came to the outpatient clinic presenting with 6 months of unquantified unintentional weight loss and jaundice. Physical examination documented only jaundice with no other alterations.

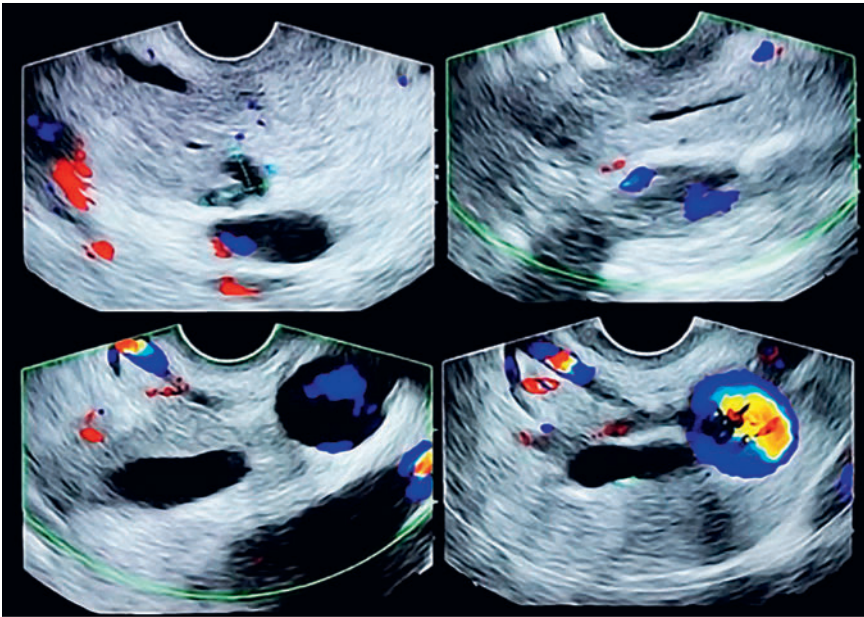
Laboratory results documented an obstructive biliary pattern (► **Table 1**). Magnetic resonance imaging (MRI) showed no evidence of neoplasia and a dilatation of the choledochus and intraductal image (► **Fig. 1**). Echo-endoscopy showed only an image suggestive of a 2-mm stone in the choledochus (► **Fig. 2**). Endoscopic retrograde cholangiopancreatography and cholangios-

copy was then performed using direct visualization by SpyGlass (Boston Scientific, Marlborough, Massachusetts, USA) in which multiple subepithelial, rounded and translucent lesions corresponding to cysts were observed, some of which ruptured spontaneously during the procedure (► **Fig. 3**, ► **Video 1**). Jaundice resolved after the procedure. Biopsies of the lesions were taken by SpyBite (Boston Scientific) without finding neoplastic pathology. After 6 months of observation, the patient is asymptomatic and continues to be followed up. Peribiliary cysts [1] are saccular structures formed from the dilatation of peribiliary glands. They are usually tiny

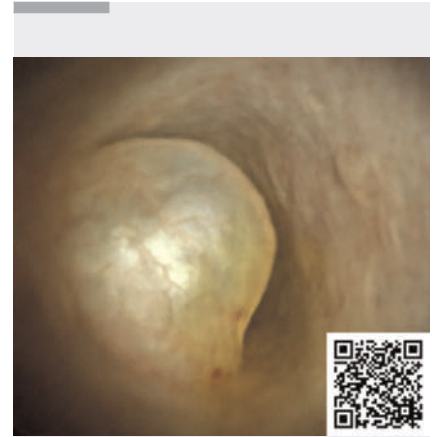
► **Table 1** Laboratory results

Laboratory	28/02/23	Reference values
Leukocytes ( $\times 10^3$ )	6220	4.5–11.3
Hemoglobin (g/dL)	14.8	12.3–15.3
Platelets ( $\times 10^3$ )	188000	150–450
Alkaline phosphatase (U/L)	710	35–104
Gamma glutamyl transferase (U/L)	774	6–42
Alanine amino transferase (ALT) (U/L)	89	0–31
Aspartate amino transferase (AST) (U/L)	86	0–32
Total bilirubin (mg/dL)	2.55	0–1
Direct bilirubin (conjugated) (mg/dL)	2.1	0–0.3
Creatinine (mg/dL)	0.83	0.51–0.95
INR	0.85	–
CA 19–9	52	0–39
ACE	2.5	0–4.3

(<10 mm) and do not communicate with the bile ducts [2]. They are mainly associated with cirrhosis and enolism (38%). They are more prevalent in the male sex (80%), with less female representation. Regarding clinical manifestations, obstructive and constitutional biliary syndrome with consequent suspicion of neoplastic obstruction of the biliary tract is the reason for consultation and clinical approach in 19% of patients [3]. With respect to detection, although computed tomography (CT) and MRI can document typical cystic lesions and thus



► **Fig. 2** Pancreatic head cyst measuring 6 × 9 mm, without communication with the main or secondary pancreatic duct. 7 mm choledochus with micro calculus of 2 mm inside. Papilla are endoscopically and endosonographically normal.



► **Video 1** Endoscopic retrograde cholangiopancreatography and cholangioscopy was performed using direct visualization. Multiple subepithelial, rounded, and translucent lesions were observed corresponding to cysts, some of which ruptured spontaneously during the procedure.

### Conflict of Interest

The authors declare that they have no conflict of interest.

### The authors

**Juan Pablo Valencia Quivano**<sup>1,2</sup>, **Juan Antonio Trejos Naranjo**<sup>3</sup>, **Ciro Andrés Murcia Cardona**<sup>2</sup>, **Andrés Cárdenas**<sup>4</sup>, **Geovanny Hernández Cely**<sup>2</sup>

1 School of Medicine and Health Sciences, Gastroenterology Program, Universidad del Rosario, Bogotá, Colombia

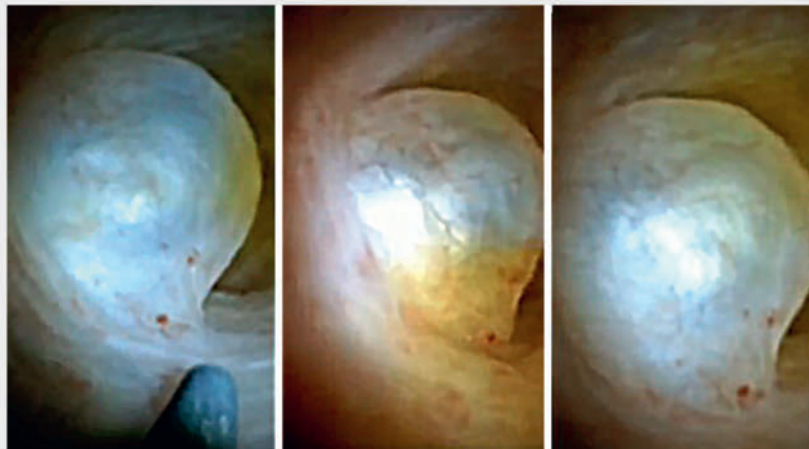
2 Department of Gastroenterology & Hepatology, Fundación Cardioinfantil Instituto de Cardiología, Bogotá, Colombia

3 School of Medicine and Health Sciences, Gastroenterology Program, Universidad Nacional de Colombia, Bogotá, Colombia

4 Institut de Malalties Digestives i Metabòliques, Hospital Clinic de Barcelona, Barcelona, Spain

### Corresponding author

**Juan Pablo Valencia Quivano, MD**  
Universidad del Rosario, Cra. 24 #63C-69, Barrios Unidos, Bogotá DC 111221, Colombia  
jpvalencia989@gmail.com



► **Fig. 3** Cholangiopancreatography: Multiple filling defects at the level of the middle choledochus, proximal choledochus, right and left hepatic duct, with dilated intra- and extra-hepatic biliary tract. Cholangioscopy: Multiple subepithelial, rounded, translucent lesions corresponding to cysts, some of which rupture spontaneously. At the level of the left hepatic duct, there is a cyst that generates partial occlusion of two ducts that is broken by SpyBite forceps.

be diagnostic in up to 48% and 64% of cases, respectively, in some scenarios cholangioscopy may be required to characterize and biopsy in order to clarify the diagnosis [4]. Regarding treatment, the authors agree that asymptomatic patients do not require specific manage-

ment or follow-up. In our case, cholangioscopy was indicated due to obstructive biliary involvement, with subsequent resolution of symptoms.

Endoscopy\_UCTN\_Code\_TTT\_1AQ\_2AK

## References

- [1] Nakanuma Y, Kurumaya H, Ohta G. Multiple cysts in the hepatic hilum and their pathogenesis. A suggestion of periductal gland origin. *Virchows Arch* 1984; 404: 341–350. doi:10.1007/BF00695218
- [2] Drenth J et al. EASL Clinical Practice Guidelines on the management of cystic liver diseases. *J Hepatol* 2022; 77: 1083–1108
- [3] Bazerbachi F, Haffar S, Sugihara T et al. Peribiliary cysts: A systematic review and proposal of a classification framework. *BMJ Open Gastroenterol* 2018; 5: e000204. doi:10.1136/bmjgast-2018-000204
- [4] Narayan RR, Juakiem WY, Poultsides GA et al. Peribiliary cysts masquerading as choledocholithiasis. *VideoGIE* 2023; 8: 351–353. doi:10.1016/j.vgie.2023.05.009

## Bibliography

Endoscopy 2025; 57: E48–E50

DOI 10.1055/a-2499-7279

ISSN 0013-726X

© 2024. The Author(s).

This is an open access article published by Thieme under the terms of the Creative Commons Attribution License, permitting unrestricted use, distribution, and reproduction so long as the original work is properly cited.

(<https://creativecommons.org/licenses/by/4.0/>)

Georg Thieme Verlag KG, Oswald-Hesse-Str. 50, 70469 Stuttgart, Germany



## ENDOSCOPY E-VIDEOS

<https://eref.thieme.de/e-videos>



*E-Videos* is an open access online section of the journal *Endoscopy*, reporting on interesting cases and new techniques in gastroenterological endoscopy. All papers include a high-quality video and are published with a Creative Commons CC-BY license. Endoscopy E-Videos qualify for HINARI discounts and waivers and eligibility is automatically checked during the submission process. We grant 100% waivers to articles whose corresponding authors are based in Group A countries and 50% waivers to those who are based in Group B countries as classified by Research4Life (see: <https://www.research4life.org/access/eligibility/>).

This section has its own submission website at <https://mc.manuscriptcentral.com/e-videos>