

# Serious neurological adverse events following immunization against SARS-CoV-2: a narrative review of the literature

Sara Eslait-Olaciregui, Kevin Llinás-Caballero, David Patiño-Manjarrés, Thomas Urbina-Ariza, Juan Fernando Cediel-Becerra and Camilo Alberto Domínguez-Domínguez 

*Ther Adv Drug Saf*

2023, Vol. 14: 1–18

DOI: 10.1177/

20420986231165674

© The Author(s), 2023.

Article reuse guidelines:  
sagepub.com/journals-  
permissions

## Abstract

Amid the coronavirus disease 2019 (COVID-19) pandemic, massive immunization campaigns became the most promising public health measure. During clinical trials, certain neurological adverse effects following immunization (AEFIs) were observed; however, acceptable safety profiles lead to emergency authorization for the distribution and use of the vaccines. To contribute to pharmacovigilance and lessen the potential negative impact that vaccine hesitancy would have on immunization programs, we conducted a review of the scientific literature concerning the epidemiological data, clinical presentation, and potential mechanisms of these neurological AEFIs. There is some epidemiological evidence linking COVID-19 vaccines to cerebral venous sinus thrombosis, arterial ischemic stroke, convulsive disorder, Guillain–Barré syndrome, facial nerve palsy, and other neurological conditions. Cerebral venous sinus thrombosis has been associated with a thrombotic thrombocytopenia induced by the vaccine, similar to that induced by heparin, which suggests similar pathogenic mechanisms (likely involving antibodies against platelet factor 4, a chemokine released from activated platelets). Arterial ischemic stroke is another thrombotic condition observed among some COVID-19 vaccine recipients. Vaccine-induced convulsive disorder might be the result of structural abnormalities potentially caused by the vaccine or autoimmune mechanisms. Guillain–Barré syndrome and facial nerve palsy may also be linked to the immunization event, possibly due to immune mechanisms such as uncontrolled cytokine release, autoantibody production, or bystander effect. However, these events are mostly uncommon and the evidence for the association with the vaccine is not conclusive. Furthermore, the potential pathophysiological mechanisms remain largely unknown. Nevertheless, neurological AEFIs can be serious, life-threatening or even fatal. In sum, COVID-19 vaccines are generally safe and the risk of neurological AEFIs does not outweigh the benefits of immunization. However, early diagnosis and treatment of neurological AEFIs are of utmost importance, and both health professionals and the public should be aware of these conditions.

Correspondence to:

**Camilo Alberto Domínguez-Domínguez**  
School of Medicine  
and Health Sciences,  
Universidad del Rosario,  
Carrera 24 #63C-69,  
111221 Bogotá, Colombia.  
[camilo.dominguez@urosario.edu.co](mailto:camilo.dominguez@urosario.edu.co)

**Sara Eslait-Olaciregui**  
**David Patiño-Manjarrés**  
**Thomas Urbina-Ariza**  
**Juan Fernando Cediel-Becerra**

Histology and Embryology  
Unit, Department of  
Biomedical Science, School  
of Medicine and Health  
Sciences, Universidad del  
Rosario, Bogotá, Colombia

Applied Biomedical  
Sciences Research Group  
(UR BioMed), School of  
Medicine and Health  
Sciences, Universidad del  
Rosario, Bogotá, Colombia

**Kevin Llinás-Caballero**  
Institute for  
Immunological Research,  
University of Cartagena,  
Cartagena, Colombia

## Plain language summary

### A review of undesired effects involving the nervous system following the administration of COVID-19 vaccines

Among the range of complications that can occur after a vaccine, some of them can affect the nervous system and its vasculature. This narrative review aims to evaluate some serious neurological conditions following COVID-19 vaccination. We searched biomedical journal databases where physicians around the globe reported different complications after the administration of different COVID-19 vaccines. Besides reports of cases in individual patients or small groups, we reviewed studies that included bigger groups of

patients (e.g. vaccinated *versus* non-vaccinated) and compared the occurrence of these events between them. We found that after the administration of a certain type of vaccine (e.g. ChAdOx1-S/Oxford, AstraZeneca vaccine), serious neurological complications were rare, with abnormal clot formation involving cerebral blood vessels being one of the most important among them. Nonetheless, other conditions have been observed after the administration of the vaccines; however, it is not certain yet if the vaccines are the actual cause of these complications.

There are some hypotheses that could explain why these adverse reactions take place after a vaccine. For instance, an abnormal immune response to the vaccine leads to the production of antibodies (i.e. proteins made by the immune system in response to the presence of a foreign substance). These antibodies trigger a response that could eventually result in clot formation. Besides, the immune response can also produce other adverse effects, including convulsive disorder, Guillain–Barré syndrome, and facial nerve palsy.

Scientific evidence suggests that vaccines are safe overall. While mild complications, such as pain at the site of injection or bruising might occur, more serious events remain rare. Furthermore, the complications derived from COVID-19 are far more likely in non-vaccinated individuals than the complications associated with the vaccine. Thus, vaccination continues to be the safest and most effective strategy to control the ongoing pandemic. However, both health professionals and the public should be aware of the possibility of serious neurological adverse reactions occurring after vaccination to allow early diagnosis and treatment.

**Keywords:** adverse effects following immunization, COVID-19, neurological complications, pharmacovigilance, vaccines

Received: 7 June 2022; revised manuscript accepted: 3 March 2023.

## Introduction

Vaccines are one of the most effective approaches for preventing infectious diseases and have helped eradicate conditions, such as smallpox and reduce the incidence of several other infections.<sup>1</sup> The outbreak of the coronavirus disease 2019 (COVID-19) pandemic, which has infected and killed millions of people, imposed an urgent need for vaccines. As a result, multiple vaccines against the severe acute respiratory syndrome coronavirus 2 (SARS-CoV-2), the virus that causes COVID-19, have been developed in record time and billions of people have been immunized all around the globe. Different platforms have been used for COVID-19 vaccines that are currently being administered, such as replication-deficient viral vectors (e.g. ChAdOx1-S developed by Oxford/AstraZeneca, Jcovden Ad26.COVS.2 developed by Janssen, Gam-COVID-Vac or rAd26-rAd25 developed by Gamaleya, and Ad5-nCoV developed by CanSino), inactivated viruses (e.g. CoronaVac developed by Sinovac), and novel mRNA-based vaccines (e.g. BNT162b2 developed by Pfizer/BioNTech and mRNA-1273 developed by Moderna).<sup>2</sup>

Adverse effects of COVID-19 vaccines are mild in most cases, consisting of local reaction in the site of injection and/or minor systemic effects like fatigue or headache. These are most likely the result of the initial immune response, characterized by the production of antiviral cytokines, particularly interferons.<sup>3</sup> On the other hand, severe COVID-19 vaccine adverse reactions, such as anaphylaxis, are rare. Although uncommon, there are reports of neurological complications following vaccination against SARS-CoV-2 in some people.<sup>2</sup> Here, we aim to review the evidence regarding serious neurological adverse effects of COVID-19 vaccines, including epidemiological studies and experimental evidence that sheds light on the potential mechanisms.

## Methods

We present a narrative review of the literature regarding the serious neurological complications of COVID-19 vaccines. We searched international biomedical journal databases, such as MEDLINE (PubMed) using the following

Medical Subject Headings (MeSH) terms and their synonyms: ('adverse effects' OR 'Drug-Related Side Effects and Adverse Reactions') AND 'COVID-19 Vaccines' AND ('Neurologic Manifestations' OR 'Nervous System'). This search included evidence published until August 2022. To identify potential additional studies for inclusion, we manually looked up the references of the articles found by the search strategy described above. Three reviewers screened the identified records based on title and abstract and then selected those to be included in this review based on the full text. A fourth reviewer was consulted in cases in which eligibility was unclear. After that, three researchers extracted the relevant information from the selected articles. Any discrepancies or missing information were resolved by consensus.

### Cerebral venous sinus thrombosis

Following the Food and Drug Administration (FDA) emergency use authorization for COVID-19 vaccines and the rapid onset of immunization campaigns around the world, a concerning number of adverse effects following immunization (AEFI) cases arose. For instance, a Mexican study reported an AEFI rate of 0.5% among BNT162b2 recipients, of which only 0.005% were serious AEFI<sup>4</sup> (Most (90.9–97%) of the Vaccine Adverse Event Reporting System (VAERS) reports were classified as nonserious events.<sup>5,6</sup>

Particularly, the scientific community focused on the emerging cases of a rare hematological syndrome with a clinical presentation similar to heparin-induced thrombotic thrombocytopenia (HITT). These thrombotic events and the accompanying thrombocytopenia in recently vaccinated individuals would soon be named vaccine-induced thrombotic thrombocytopenia (VITT).<sup>7</sup> VITT is a consumption coagulopathy that can present with cerebral venous sinus thrombosis (CVST) and/or splanchnic thrombosis.<sup>8–11</sup> Although these complications imply significant risk per se, the fact that VITT might be associated with CVST increases its fatal potential and the clinician's concerns.

Aiming to determine whether the risk–benefit ratio is affected by this AEFI, epidemiological studies have been carried out. A population-based cohort study compared the rate of thrombotic

events between the recipients of the ChAdOx1-S vaccine and the general population. A higher-than-expected rate of CVST was detected in the immunized cohort: 11 excess venous thromboembolic events, including 2.5 excess CVST per 100,000 vaccinations. Furthermore, a 20.25 [95% confidence interval (CI): 8.14–41.73] standardized morbidity ratio for CVST was obtained.<sup>12</sup> Based on the results, CVST could be considered a rarely occurring complication of ChAdOx1-S and potentially other adenoviral vector vaccines (e.g. Ad26.COV2.S, rAd26-rAd2, and Ad5-nCoV). Although results are based on a true population study, interpretation should be cautious because there is not sufficient evidence to determine whether a specificity criterion (i.e. that the vaccine is the only cause of the event) is met.<sup>13</sup> In addition to this, the vaccinated cohort was fundamentally composed of health care workers,<sup>12</sup> a sample that might not accurately represent the general population that is being immunized and its risk factors, becoming a potential source of bias.

In respect to mRNA-based vaccines (i.e. BNT162b2 or mRNA-1273), Dias *et al.*<sup>14</sup> reported two cases of CVST following administration of BNT162b2. One of these patients had iron deficiency anemia, a condition that is considered a rare cause of thrombosis by some authors.<sup>15</sup> In addition to that, she was taking combined oral contraceptives, which are well-known prothrombotic risk factors<sup>16</sup> and thus might have also contributed to thrombogenesis in this case. However, the common use of these medications makes their contributory role arguable. The other patient had been diagnosed with multiple conditions that could have contributed to clot formation, such as hypertension, diabetes, and dyslipidemia.<sup>14</sup>

Furthermore, a retrospective cohort study compared the absolute risk of CVST following a COVID-19 diagnosis with the absolute risk of CVST following immunization with an mRNA vaccine against COVID-19. The incidence of CVST following infection was significantly higher than the incidence observed in the immunized cohort [relative risk (RR) = 6.33, 95% CI: 1.87–21.40,  $p = 0.00014$ ]. The risk for thrombocytopenia, a cornerstone in the diagnosis of VITT, was also compared between cohorts. An RR of 23.96 (95% CI: 21.49–26.73,  $p = 0.0001$ ) supports the fact that thrombocytopenia is significantly more likely after the SARS-CoV-2 infection than

following vaccination.<sup>17</sup> This evidence contributes to the risk–benefit analysis as it demonstrates that infection by the SARS-CoV-2 virus implies a significantly higher risk for CVST and thrombocytopenia than the potential risk associated with vaccination. Moreover, the observed incidence of CVST was compatible with the lowest estimate of the baseline rate in the United States.<sup>17</sup> These findings suggest that mRNA vaccines are not linked to an increased rate of CVST. However, CVST associated with VITT is a very rare syndrome. However, some patients could receive an inaccurate diagnosis and healthcare systems might not have a strong pharmacovigilance framework, leading to underreporting that could partially explain the low incidence.

Considering that VITT is a recently described clinical entity, it is necessary to elucidate the clinical spectrum of vaccine-associated CVST that enables early patient detection and further pharmacovigilance. CVST secondary to VITT presents a wide continuum of neurological manifestations, ranging from subtle and often disregarded complaints to more alarming symptomatology. For instance, some patients who received adenoviral vector vaccines, such as ChAdOx1-S or Ad26.COV2.S vaccine presented with headaches but no other neurological symptoms upon admission.<sup>10,18</sup> Conversely, some of these patients debut with remarkable neurological symptoms, such as vertigo, hemianopia, aphasia, seizures, hemiparesis, behavioral disturbances, and altered states of consciousness.<sup>19–21</sup> Of note, there seem to be no significant differences between the manifestations of CVST among patients who received mRNA-based vaccines *versus* those immunized with adenovirus-based vaccines. Persistent headaches, malaise, vomiting, and motor deficits were common symptoms to CVST associated with both vaccine technologies.<sup>14,18,22–24</sup>

Regardless of the initial clinical presentation, a rapid neurological deterioration could be expected. For instance, a 32-year-old male developed thunderclap headache, left-sided incoordination, and hemiparesis 9 days after the ChAdOx1-S vaccine. In the span of 3 h, his Glasgow Coma Scale (GCS) decreased from 15 to 4, requiring intubation and ventilation; while pupillary responses deteriorated and became fixed and dilated. At that time, a computed tomography (CT) scan revealed clot, significant

cortical edema, and evidence of cerebellar herniation and brainstem death.<sup>25</sup>

In light of the above, CVST must be promptly identified. Both clinicians and patients should pay attention to any neurological symptoms, even those mild, that onset particularly 48 h after the administration of a vaccine and should be aware of the possibility of serious neurological AEFIs. In addition, low platelet counts should be considered as a warning sign since it is a hallmark feature of this condition. A complete hematology profile (complete blood count, reactive C protein, erythrocyte sedimentation rate, D-dimer, prothrombin time, and partial thromboplastin time) together with imaging studies might be enough to determine whether the clinical findings are in line with an expected vaccine reactogenicity or indicate a serious neurologic AEFI. Patients affected by VITT present with varying degrees of thrombocytopenia<sup>11,21,25–28</sup> elevated D-dimer levels, and low or borderline fibrinogen levels, associated in some cases with prolonged clotting times.<sup>29,30</sup> As stated before, there is a possibility of rapid deterioration. Therefore, further and thorough continuing clinical observation is warranted.

A detailed differential diagnosis allows a proper assessment of alternative explanations for the aforementioned hematologic disturbances. Considering that recent research has established COVID-19 as a prothrombotic condition, potentially inducing arterial and venous thrombosis,<sup>31</sup> an active SARS-CoV-2 infection must be ruled out. The time of onset of symptoms and vaccine administration should be carefully investigated, with the aim to determine a potential temporal association. Besides, although prothrombotic conditions – some of them highly prevalent – cannot fully explain the overall occurrence of CVST in the population, several other prothrombotic pathologies must be excluded in each case before associating CVST with the vaccination event.

Although a temporal relationship between the vaccination event and symptom onset has been consistently reported, there are reasonable alternative etiologies and predisposing factors that should be considered. Many patients have presented thrombotic events following vaccination, but aside from the vaccine, they usually present numerous pre-existing conditions that behave as risk factors associated with clot formation. For

instance, in a report of three cases of VITT after the ChAdOx1-S vaccination, a 61-year-old woman diagnosed with bilateral pulmonary embolism also had a history of hypertension and a high body mass index ( $38 \text{ kg/m}^2$ ).<sup>32</sup> Both obesity and hypertension have been regarded as prothrombotic conditions.<sup>29,30</sup> Along the same line, a case of a 36-year-old female with diabetes mellitus on oral hypoglycemic therapy was diagnosed with CVST among other conditions.<sup>29</sup> They attributed the condition to the vaccine due to the temporal relationship, however, it is important to consider that diabetes mellitus is a disease that facilitates clot formation.<sup>33,34</sup> Nevertheless, CVST cases have been reported in patients that did not present overt prothrombotic pre-existing conditions.<sup>30</sup>

In addition to the complete hematology profile, clinically oriented imaging studies are an essential component of the diagnostic workup. Several findings have been described in patients that developed VITT syndrome with central nervous system (CNS) compromise. In patients with focal neurological symptoms, there is a trend toward the thrombotic occlusion of sigmoid and transverse sinuses, as well as for the presence of hemorrhagic events involving the cerebellum and the frontal region of the brain.<sup>18,21,25–27,32</sup> In addition, the thrombotic events in VITT patients can also affect other venous sites besides the cerebral veins (e.g. superior ophthalmic vein), as well as arteries (resulting in concomitant arterial occlusions).<sup>11,35</sup>

As for the treatment, several authors reported favorable clinical outcomes in VITT patients following therapies that included intravenous immunoglobulin (IVIG).<sup>10,11,18,20</sup> In line with this, IVIG has been demonstrated to be effective in ceasing platelet activation leading to a rapid platelet count increase in patients with spontaneous HITT, which is thought to share a common pathophysiological mechanism with VITT.<sup>36</sup> More specifically, spontaneous HITT is characterized by autoimmune platelet activation induced by heparin-independent antibodies in the absence of heparin exposure. This fits with our current comprehension of the pathogenesis of VITT, which will be expanded later on.

Regarding the mechanism of VITT secondary to ChAdOx1-S vaccination, it seems to be triggered by the synthesis of IgG antibodies against platelet factor 4 (PF4). The presence of serum immune

complexes in VITT patients with a mixture of antibody specificities similar to what is observed in HITT patients suggested similar underlying mechanisms in both conditions.<sup>18</sup> In HITT, because of the positively charged PF4 binding to the negatively charged heparin, a PF4/heparin complex (also called PF4/polyanion) forms as a tetramer.<sup>37,38</sup> In response, the immune system of genetically predisposed patients produces antibodies against PF4/heparin complexes. The fragment antigen-binding (Fab) region of IgG binds to PF4/heparin complexes, while the fragment crystallizable (Fc) region of these antibodies binds to Fc $\gamma$  receptor IIa (Fc $\gamma$ RIIa) on platelets. This antigen–antibody–receptor interaction leads to the expression of P-selectin on the platelet surface and results in Fc $\gamma$ RIIa cross-linking. As a consequence, platelet activation and consumption, together with the release of procoagulant factors from the platelet and the endothelium itself, might lead to thrombin formation and – potentially – life-threatening thrombotic events.<sup>32,37</sup> Similarly, in VITT, antibodies against PF4 recognize eight surface amino acids within its heparin-binding site, allowing PF4 tetramers to cluster and form immune complexes, which then activate platelets in a Fc $\gamma$ RIIa-dependent fashion.<sup>38</sup>

Procoagulant platelets are characterized by the expression of activation markers; namely, P-selectin (also called CD62 P) and phosphatidylserine (PS).<sup>39</sup> Compared with sera from healthy controls, sera from VITT patients induced significant changes in the distribution of CD62 P/PS positivity in platelets from healthy donors ( $p = 0.009$ ).<sup>40</sup> The procoagulant effect of platelets is partially explained by the strictly regulated translocation of membrane phospholipids, including PS. Following platelet activation, the enzyme scramblase will mediate the translocation of PS from the inner to the outer membrane surface. Once PS is available in the outer leaflet, it will ease the formation of the intrinsic tenase and the prothrombinase complexes, thus favoring thrombin synthesis during the propagation phase of coagulation.<sup>39</sup> Furthermore, P-selectin plays a key role in the pathophysiology of thrombosis. This transmembrane protein is found inside the alpha granules of platelets and cellular activation leads to its transport to the platelet cell membrane. Surface-expressed P-selectin mediates platelet-leukocyte and platelet-platelet interaction, thus contributing to the formation of cellular

aggregates, upregulation of tissue factor, and synthesis of procoagulant molecules.<sup>41</sup> Consequently, induction of procoagulant markers such as P-selectin and PS by anti-PF4 immunoglobulins could presumably explain thrombotic events observed in VITT.

Increased levels of anti-PF4 antibodies have been identified in patients with VITT, with or without CVST.<sup>11,18,28,32,40</sup> Consistent with other reports, high-titer anti-PF4 IgG was detected in the sera of 8 out of 8 patients diagnosed with VITT following ChadOx1-S vaccination, five of which exhibited clinical evidence of CVST.<sup>40</sup> IgG binding to platelets was higher after incubation with sera from VITT patients compared with sera from healthy controls ( $p = 0.026$ ). Stronger binding of IgG antibodies against PF4 was also detected in the sera of VITT patients ( $p < 0.0001$ ).<sup>40</sup> Collectively, these results point out that the anti-PF4 antibody-mediated platelet activation is a likely mechanism underlying VITT and, in turn, vaccine-related CVST.

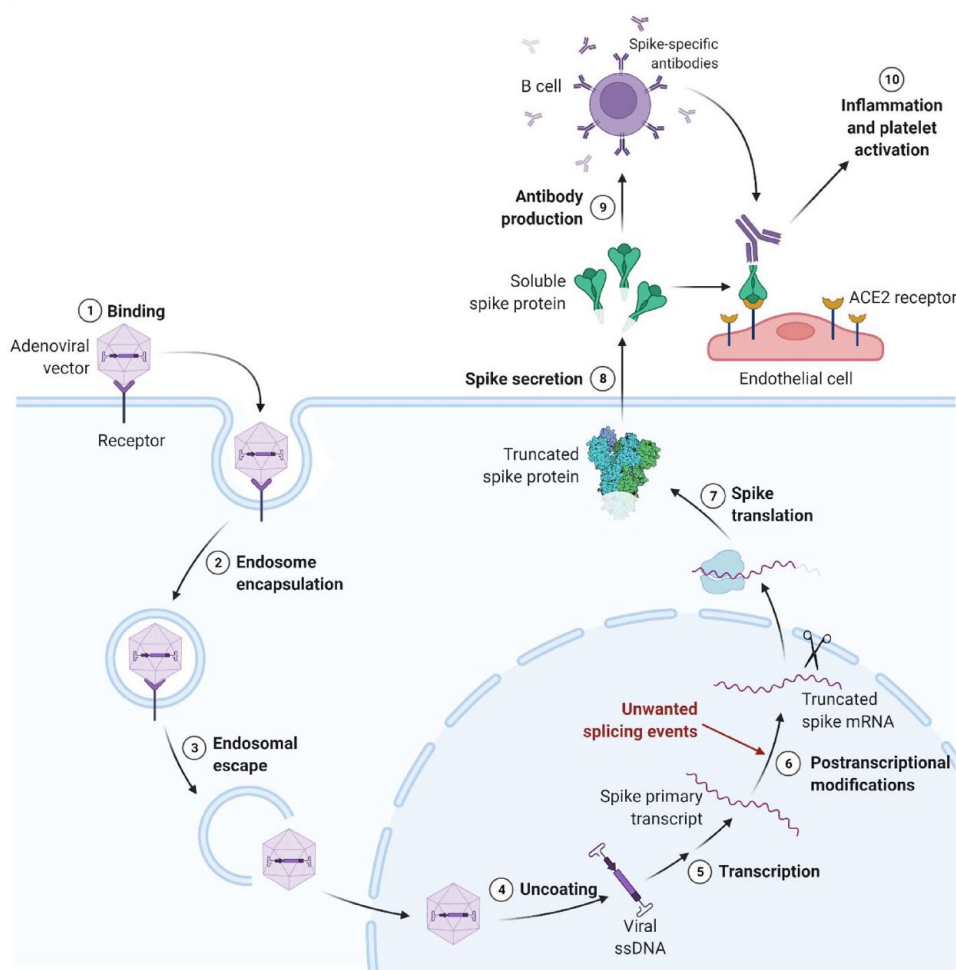
The positive clinical response to IVIG in VITT patients is in line with the involvement of anti-PF4 antibodies and the Fc $\gamma$ RIIIa in the pathogenesis of VITT. The mechanism of action of IVIG seems to be related to the inhibition of the Fc $\gamma$ RIIIa receptor by monomeric IgG.<sup>42</sup> Consistently, an *in vitro* study demonstrated that platelet activation was completely inhibited by a monoclonal antibody that blocks the Fc $\gamma$ RIIIa and by high doses of IgG.<sup>40</sup>

On the other hand, among a group of 41 healthy vaccinees, four individuals (9.8%) seroconverted with IgG antibodies against PF4 complexes within 14 days of vaccination. Moreover, the sera from these patients did not induce platelet activation.<sup>40</sup> This supports the possibility of asymptomatic seroconversion. Taking this into account, we could assume that a small fraction of vaccinees seroconverts to IgG against PF4 complex, and even a smaller fraction of such patients develops VITT. We hypothesize that genetic factors underlie the susceptibility to produce antibodies against PF4 and to develop VITT in consequence.

Furthermore, there is some experimental evidence supporting the involvement of RNA splicing resulting in spike protein solubilization as the underlying mechanism of VITT associated with

vector-based vaccines (Figure 1). Following the entry of adenoviral DNA, the gene encoding the SARS-CoV-2 spike protein is transcribed inside the nucleus. Subsequently, arbitrary splicing events occur within the open reading frame of this transcript, most – if not all – of them resulting in shorter protein variants, disrupting the spike protein upstream of the membrane anchor, thus rendering it soluble.<sup>9</sup> Most likely, when such soluble proteins are systemically available, they bind to angiotensin-converting enzyme 2 (ACE2) receptors in the endothelial cells, while the immune system starts to produce antibodies against this viral protein, inducing a massive inflammatory response, characterized by antibody-dependent cell-mediated cytotoxicity and/or complement-dependent cytotoxicity.<sup>9</sup> Both the endothelial activation and the immune response would then trigger the coagulation cascade, thus predisposing to clot formation. Besides, the spike protein could also disrupt the integrity of the blood–brain barrier (BBB) and enhance platelet activation.<sup>43,44</sup> Because of the non-unidirectional blood flow and the lack of typical venous valves in the CNS sinuses, the soluble spike protein stays in these vessels for a longer period, thus raising the probability of binding to endothelial cells expressing the ACE2 receptor. This could explain the increased frequency of thromboembolic events in this unusual site, compared with other regions in the body.<sup>9</sup>

Once we have discussed the potential mechanisms for VITT and CVST associated with adenoviral-based vaccines, it is worth contemplating aspects regarding mRNA vaccines. Studies in nonhuman primates have shown that mRNA-based vaccines skew the immune response toward a T helper (Th)1 profile, characterized by the production of cytokines, such as interferon-gamma, tumor necrosis factor (TNF), and interleukin (IL) 2 (IL-2).<sup>45,46</sup> Under normal circumstances, endothelial cells maintain a balance between a thrombogenic and non-thrombogenic state; whether thrombosis is favored or not depends partially on available cytokines. TNF, as well as other cytokines, favors endothelial tissue factor expression,<sup>47</sup> which is well known for being the main initiator of the coagulation cascade. Thus, it is reasonable to hypothesize that mRNA vaccines induce a Th1 cytokine profile, which could be linked to prothrombotic pathways.



**Figure 1.** Proposed mechanism of VITT associated with vector-based vaccines.

Created with BioRender.com.

For details, please refer to the main text. Adenoviral vectors contain DNA encoding the spike protein, which is transcribed inside the nucleus. The resulting RNA undergoes posttranscriptional modifications, including splicing to remove introns. Unwanted splicing events might result in a truncated spike mRNA, which is later translated to produce a spike protein lacking the membrane anchor. This soluble spike protein would then bind to ACE2 receptors on the membrane of endothelial cells and activate the immune system, thus resulting in inflammation, platelet activation, and – overall – a prothrombotic state.

ACE2, angiotensin-converting enzyme 2; mRNA, messenger ribonucleic acid; ssDNA, single-stranded deoxyribonucleic acid.

Experimental evidence regarding the effects of the SARS-CoV-2 spike protein sheds light on the potential mechanisms underlying vaccine-associated CVST. First, the spike protein directly affects the BBB. Electric cell-substrate impedance and a three-dimensional (3D) microfluidic model showed that the spike protein disrupts the integrity and increases the permeability of the BBB.<sup>43</sup> The SARS-CoV-2 spike protein also induces a proinflammatory phenotype in cultured human brain endothelial cells, with increased expression of adhesion molecules, proinflammatory cytokines, chemokines, and matrix

metalloproteinases (MMPs).<sup>43</sup> MMPs are endopeptidases thought to digest tight junction proteins (i.e. claudin-1, claudin-5, occludin, and zonula occludens-1), as well as basement membrane proteins in the BBB, thus disrupting its integrity.<sup>48</sup> When integrity and permeability of the BBB are altered, inflammatory cell migration into the brain parenchyma could be favored. Furthermore, the heightened expression of surface adhesion molecules could contribute to the inflammatory cascade and cellular aggregation initiating prothrombotic pathways. In addition, spike glycoprotein interaction with the ACE2

receptor results in enhanced platelet activation, including an increased expression of procoagulant platelet markers.<sup>44</sup>

Taken together, these results point out that mRNA-based vaccines might promote thrombotic events by the induction of a prothrombotic cytokine profile. Alterations in the BBB and platelet function could also be involved. However, more studies are needed to elucidate the potential mechanisms of VITT associated with these vaccines.

### Arterial ischemic stroke

Besides CVST, another potential thrombotic AEFI compromising the nervous system is arterial ischemic stroke. Epidemiological data support that neurological thrombotic AEFIs are rare. For instance, the reported incidence of acute stroke in Mexico associated with six different vaccines (BNT162b2, ChAdOx1 nCov-19, Gam-COVID-Vac, CoronaVac, Ad5-nCoV, and Ad26.COV2-S) was 0.71 cases per 1,000,000 administered doses.<sup>49</sup> Additional studies are required to determine whether VITT has a predilection – if any, to cause venous or arterial thrombotic events. Arterial thrombosis as a manifestation of VITT appears to be less common than venous thrombosis.<sup>50</sup> In fact, cerebral arterial thrombosis accounts only for 12% of ischemic events related to VITT, compared with venous thrombosis that contributes at least with 50% of the cases.<sup>51</sup> In contrast, a large retrospective study found that the acute ischemic stroke corresponded to 75% of the overall stroke incidence, while cerebral venous thrombosis was present only in 3.6% of the cases.<sup>49</sup> Although more robust studies are missing, it seems that some vaccine technologies are more prone to cause arterial ischemic events than others. mRNA vaccines such as BNT162b2 and Moderna are related to a higher incidence of arterial events. In contrast, the proportion of arterial *versus* venous ischemic events following viral vector vaccines seems to be more evenly distributed.<sup>52</sup>

Acute ischemic stroke observed after COVID-19 vaccines are predominantly due to large artery atherosclerosis (34.9%), as has been reported in Mexico- and Indonesia-based studies.<sup>49,53</sup> Moreover, arterial ischemic events following immunization were predominantly reported in

females, who developed motor symptomatology associated with anterior cerebral circulation occlusion. For instance, a 42-year-old female developed left hemiplegia 2 weeks after a ChAdOx1-S dose. Imaging revealed bilateral anterior cerebral artery (ACA) and right middle cerebral artery (MCA) occlusion.<sup>54</sup> Left hemiparesis was also de clinical manifestation in a 79-year-old male, in whom brain magnetic resonance imaging (MRI) showed lacunar infarcts in anterior circulation territories.<sup>53</sup> Similarly, involvement of the proximal segment of MCA was observed in a 51-year-old female who developed right-sided hemiplegia, hemianopia, and global aphasia 7 days after a ChAdOx1-S vaccine.<sup>55</sup>

This case study is compatible with the analysis of large retrospective studies in which almost two-thirds of the arterial events were observed in females,<sup>52</sup> almost 90% of patients presented an anterior circulation stroke mainly involving the MCA, and motor deficit was the most common symptom (75%) followed by language deficits.<sup>50</sup>

Laboratory findings in patients who developed arterial stroke were similar to those in patients with CVST (i.e. thrombocytopenia, high D-dimer levels, low fibrinogen, and positive anti-PF4 IgG antibodies).<sup>54,55</sup>

These similarities suggest a common pathological pathway related to a coagulopathy induced by the vaccine. Nevertheless, some patients exhibit different paraclinical findings. For instance, a female patient with left hemiparesis due to occlusion of the M1 segment of the right MCA had a reduced platelet count and elevated D-dimer levels but negative ELISA for anti-PF4 antibodies.<sup>50</sup>

Among patients affected by acute ischemic stroke following immunization, pro-atherosclerotic risk factors are common, as well as a personal history of past ischemic strokes.<sup>53</sup> Hence, we hypothesize that such events could also be attributed to the vaccine recipients' underlying conditions, such as hypertension, diabetes mellitus, smoking, and dyslipidemia.<sup>53,56</sup> Even so, we cannot rule out that vaccine administration further predisposed for such outcomes.

Despite the fact that cerebral ischemic events have been reported all over the world, it has been

reported that recipients of ChAdOx1-S or BNT162b2 recipients do not show an increased short- or long-term risk of acute ischemic stroke, which supports the safety of COVID-19 vaccines.<sup>52,57</sup>

### Convulsive disorder

Among the adverse effects following COVID-19 vaccines, some authors reported patients presenting with convulsive disorder. Essentially, two etiological groups can be identified: first, seizures due to acquired structural etiologies (i.e. stroke) in which the vaccine is suspected to be the cause; and second, seizures secondary to an unknown etiology (in which an autoimmune mechanism could be hypothesized). Although temporality points to an association with the vaccine, some of these cases do not offer solid evidence to establish a causal connection.

Regarding the first category, some seizures occurred in the context of immune-related venous thrombosis or arterial occlusion. For instance, a 55-year-old female who developed ocular and neurological symptoms 10 days after the first dose of the ChAdOx1-S vaccine was diagnosed with secondary immune thrombocytopenia and bilateral superior ophthalmic vein thrombosis. Despite the treatment, she developed transient mild right-sided hemiparesis and aphasia, followed by right-sided focal seizures. The new-onset clinical presentation correlated to an ischemic stroke in the left parietal lobe, corresponding to MCA territory.<sup>35</sup> Similarly, another 55-year-old female experienced transitory aphasia, right-sided hemiparesis, generalized seizures, and coma 10 days after receiving the first dose of ChAdOx1-S vaccine. Laboratory findings were compatible with VITT, including elevated levels of antibodies against PF4/polyanion complexes. In addition, neuroimaging revealed occlusion of the right internal carotid artery terminus, as well as an obstruction of the left MCA.<sup>11</sup> Besides, a 22-year-old female developed self-limited generalized seizures 7 days after ChAdOx1-S vaccination. She was diagnosed with VITT associated with CVST.<sup>19</sup>

Focal cerebral ischemia caused by thrombosis has been associated with metabolic dysfunction, local ionic shifts, and the release of excitotoxic neurotransmitters. As a result, the membrane potential

is offset, producing a hyperexcitable state and a lower seizure threshold.<sup>58,59</sup> In addition, a sizable proportion of CVST patients present with seizures.<sup>60,61</sup> Therefore, it is likely that seizures in this category are not due to a direct epileptogenic effect of immunization but secondary to CVST or arterial occlusion probably associated with VITT.

Concerning the second category, one case that exemplifies this phenomenon is a 42-year-old female who presented with new-onset refractory status epilepticus 10 days after vaccination with ChAdOx1-S, characterized by generalized tonic-clonic seizure. She continued to experience these seizures without improvement despite antiepileptic treatment, thus requiring coma induction. Remarkably, the patient improved after antiepileptic dosage optimization, immunotherapy with pulse steroid therapy, and plasma exchange.<sup>62</sup> Considering that the status epilepticus was not febrile-related, no structural abnormalities besides post-ictal changes were identified via MRI, and considering that the patient resolved upon immunotherapy, the observed neurological manifestations might be immune-mediated.

Evidence of convulsive disorders following vector-based vaccines is restricted to case reports. No large epidemiological studies have explored this association so far. Regarding mRNA vaccines, a Mexican-based cohort study focusing on BNT162b calculated a ratio of 0.99 seizures per 100,000 doses. In addition, the lifetime prevalence of epilepsy in Latin America is similar to the prevalence observed in this study. This suggests that mRNA-based vaccines might not be associated with a higher frequency of new-onset seizures.<sup>4</sup>

To the extent of our knowledge, there are no experimental studies that explore the relationship between hyperexcitable states and COVID-19 vaccines or the mechanisms that could be responsible for this association. Nevertheless, suboptimal therapeutic response with conventional antiepileptics, in contrast to the observed success of anti-inflammatory medications in this setting, suggests an involvement of the immune response in the pathogenesis of these seizures, given a proper exclusion of other etiologies. The immune-mediated convulsive syndrome is the articulated effect between infiltration by immune cells (i.e. Th cells, B cells, neutrophils, and monocytes)

and inflammatory mediators, and the response of cerebral tissue resident cells.<sup>63</sup> Trauma, stroke, infection, or febrile status can cause neuroglial and endothelial cell activation. As a result, proinflammatory cytokines, such as IL-1 $\beta$  and TNF- $\alpha$ , are released. The subsequent inflammatory cascade increases intracellular calcium currents and provokes ion channel dysregulation, triggering epileptogenesis.<sup>58,64</sup> Similarly, during COVID-19, neuronal hyperexcitability is thought to be induced by reactive astrogliosis, activation of the microglia, cytokine storm, and BBB dysfunction.<sup>65</sup> However, it should be acknowledged that the scenario of an active SARS-CoV-2 infection is different from the post-immunization response.

Considering all this, immune-mediated epileptogenesis might be a plausible mechanism for the seizures following immunization against COVID-19. However, further experimental studies are needed to elucidate the pathophysiology of this vaccine-related condition. Until then, these ideas remain speculative.

### Guillain-Barré syndrome

Guillain-Barré syndrome (GBS) is an immune-mediated polyradiculoneuropathy that occurs after some respiratory or gastrointestinal infections. Culprit pathogens such as *Campylobacter jejuni* and some viruses, such as the hepatitis E virus, have been associated with the development of the disease via a molecular mimicry mechanism. For instance, a subset of *C. jejuni* has lipooligosaccharides that can mimic the carbohydrate moiety of gangliosides in peripheral nerves triggering a humoral immune response that can result in nerve dysfunction.<sup>66</sup> GBS is often characterized by a rapidly progressive, symmetrical weakness of the limbs, usually with hyporeflexia or areflexia. Even though it can be self-resolving, it could be life-threatening in certain cases, as it causes respiratory muscle compromise.<sup>66,67</sup> Cerebrospinal fluid (CSF) analysis, nerve conduction study, as well as an MRI, are relevant for the diagnosis. Many patients with GBS are treated with IVIG, but some of them may require mechanical ventilation due to respiratory failure.

GBS has an incidence of 0.81–1.89 (median: 1.11) per 100,000 person-years, being more common in men than women (ratio 3:2).<sup>66</sup> Moreover, some rare cases have been reported following

COVID-19 vaccination, but considering that it has life-threatening complications, such cases have raised public concern.

In a prospective observational study from Mexico after the first dose of BNT162b2, neurologic adverse effects among 704,000 vaccinees were assessed. Overall, three GBS cases (0.43 per 100,000 doses) were confirmed by clinical, laboratory, and electrophysiologic studies. Notably, all these patients had confirmed gastrointestinal infections and were negative for COVID-19. On the other hand, in the United Kingdom, a country with high vaccination rates, the Medicine and Health Care Products Regulatory Agency has reported that 491 patients developed GBS after the ChAdOx1-S vaccine between 1 January 2021 and 30 March 2022.<sup>68</sup> Some reports of this syndrome following COVID-19 immunization exhibit a temporal association with the vaccine and a classical clinical picture of GBS, including improvement upon IVIG administration in some cases.<sup>67,69</sup> However, to the best of our knowledge, the causality of this association has not yet been proven.

More recently, a report from surveillance data from the Vaccine Safety Datalink of the United States described the incidence of GBS following administration of Ad26.COV2.S, BNT162b2, or mRNA-1273 vaccines in 10,158,003 people (from 13 December 2020 to 13 November 2021). GBS was rare among those receiving these vaccines: GBS incidence after the mRNA vaccines was similar to the expected background rate while the incidence after Ad26.COV2.S was slightly greater. The adjusted RR of GBS during the 21 days following Ad26.COV2.S was 20.56 compared with mRNA vaccines ( $p < 0.001$ ), corresponding to 15.5 excess cases per million Ad26.COV2.S recipients.<sup>70</sup> Thus, there was a small but significant increase in the risk of GBS after Ad26.COV2.S, which is consistent with previous reports.<sup>71</sup> Similar to these findings, a study conducted in Mexico that involved over 80 million doses of seven COVID-19 vaccines (mRNA-1273, BNT162b2, ChAdOx1-S, rAd26-rAd5, Ad5-nCoV, Ad26.COV2.S, and CoronaVac) found an overall incidence of 1.19 cases per million administered doses, the highest incidences were found among Ad26.COV2.S and BNT162b2 recipients.<sup>72</sup> Furthermore, an analysis of the World Health Organization pharmacovigilance

database found a frequency of 0.13% of GBS and its variants following vaccination with either ChAdOx1-S, BNT162b2, or mRNA-1273, which was low but higher when comparing it against the entire database.<sup>73</sup> However, it was not greater than the risk of GBS associated with influenza vaccine.<sup>73</sup> Overall, these data suggest that, although the risk for GBS may be higher after administration of certain COVID-19 vaccines, it is still low and similar to the background risk in most cases, therefore not surpassing the benefit of immunization.

A case series also reported two cases of GBS after receiving the BNT162b2 vaccine in two older women with a history of diffuse large B-cell lymphoma. The Adverse Drug Reaction Probability Scale (also called Naranjo scale) was calculated for these cases, and a score of 7 was obtained. Even though this is compatible with the GBS being a probable adverse drug reaction of the vaccine, the B-cell dysfunction presented by the patients is a potential predisposing factor for the disease.<sup>74</sup>

A rare variant of GBS, characterized by bifacial weakness with paresthesia and facial diplegia as the only motor manifestation, has been reported in some of the cases of this syndrome following COVID-19 vaccination, particularly the ChAdOx1-S vaccine.<sup>75</sup> Interestingly, this GBS variant has also been described during SARS-CoV-2 infection, which suggests an involvement of the immune response to the spike protein. The observed latency period (11–22 days) supports the biological plausibility of this association, considering that the maximal immune response from vaccination is expected to occur in a similar window of time.<sup>75</sup>

GBS has been linked to certain vaccines over the years. As mentioned before, some data indicate an association between influenza vaccine and GBS, but the evidence is not conclusive.<sup>66,76</sup> GBS secondary to the influenza vaccine is considered an immune-mediated event. Considering that GBS post-COVID-19 vaccination has a latency similar to GBS post-influenza (approximately 3 weeks), an immune-mediated mechanism is also suggested for the former.<sup>77</sup> There is no evidence regarding the precise mechanisms that underlie post-vaccination GBS. However, it is reasonable to hypothesize a role for the

production of certain cytokines, like IL-6, IL-12, IL-15, and TNF- $\alpha$ , by macrophages and microglia cells, similar to what happens during an active SARS-CoV-2 infection.<sup>67</sup> This cellular activation and cytokine production can result in chronic inflammation and brain damage. In addition, vaccine product-related reaction can also play a role in vaccine-induced GBS, since certain contaminating proteins or other vaccine components could cause anti-ganglioside antibody production involved in the disease.<sup>78</sup>

### Facial nerve palsy

Facial nerve palsy (FNP) is a mononeuropathy that has been diagnosed among COVID-19 vaccine recipients. Therefore, it is currently being assessed as a possible AEFI. A similar phenomenon occurred following influenza and meningococcal vaccines, but a causal link has not yet been established. Overall, the cause of FNP is unknown in most cases (70% of cases), which is known as idiopathic FNP or Bell's palsy (BP).<sup>79</sup>

Epidemiological studies play a key role in the process of assessing causality; thus, a cautious interpretation of data is essential. An FDA briefing document regarding a meeting of the Vaccines and Related Biological Products Advisory Committee included the report of four BP cases among the recipients of the BNT162b2 vaccine *versus* none in the control group.<sup>80</sup> Although these results raised concerns given the imbalance of BP cases between vaccine and placebo groups, there is no certain causal relationship with the vaccine because the observed incidence in the group of vaccinees was not higher than the expected for the general population.<sup>80</sup> Similarly, in the mRNA-1273 phase 3 trial, four cases of BP were reported among 30,420 participants randomized on a 1:1 basis. It is important to note that three of the cases were in the vaccine arm and one of them was in the placebo arm.<sup>81</sup> In an Israeli case-control study, 37 patients with new-onset acute FNP were compared with matched controls. The study design aimed to minimize bias by controlling for variables, such as age, sex, and seasonality risk factors. Results showed that there was not an increase in the number of admissions due to FNP compared with previous years. Accordingly, the BNT162b2 vaccine was not identified as a risk factor for FNP in this study.<sup>82</sup> However, the possibility of an

association between these vaccines and BP should be closely monitored.

FNP is characterized by very noticeable clinical features. The typical clinical presentation includes sudden onset of unilateral facial paralysis and other signs and symptoms, such as eyebrow ptosis, inability to close the eye, disappearance of the nasolabial fold, and ptosis at the affected corner of the mouth. The initial diagnostic approach should be meticulous due that it is considered an exclusion diagnosis and other pathologies (e.g. GBS, herpes zoster, sarcoidosis) should be pondered.<sup>83</sup> Prior to the establishment of FNP as an AEFI, it is necessary to consider pre-existing conditions as potential triggers or risk factors leading to the disease. Diabetes, obesity, hypertension, pre-eclampsia, and upper respiratory disease have been previously described as risk factors for FNP and should be taken into consideration.<sup>79</sup> However, these pre-existing conditions could not have triggered the condition by themselves in the absence of vaccine exposure.

The aforementioned considerations are depicted in a case series that included nine patients reported to have new-onset acute FNP. Among these, four patients had hypertension, a condition that could have contributed to the development of the disease.<sup>84</sup> Similarly, BP was described in a 57-year-old female who had a past medical history of three episodes of BP and hypertension secondary to corticosteroid administration. Interestingly, the latency periods from vaccine administration to FNP development described throughout the reviewed literature are highly variable, ranging from a few hours to 30 days after receiving a COVID-19 vaccine dose.<sup>84,85</sup>

Several hypotheses aim to explain BP secondary to the COVID-19 vaccination: interferon production, molecular mimicry, bystander effect, among others. FNP has been reported as a rare possible complication of interferon therapy. Considering that COVID-19 vaccines, such as BNT162b2, have been demonstrated to induce an activation of the innate immune system, including the production of interferons, this mechanism is biologically plausible.<sup>86</sup> Moreover, molecular mimicry between vaccinal antigens and self-antigens present in the facial nerve could result in the production of cross-reactive antibodies. A bystander effect, in which

self-antigens are presented at the site of the immune response elicited by the vaccine and the subsequent activation of dormant autoreactive lymphocytes, would trigger an immune response responsible for nerve inflammation.<sup>82,86</sup>

### Others

Other reported neurological AEFIs are even less frequent than the ones discussed so far. Considering that vaccination campaigns are still being carried out and further vaccine boosters are expected to come, more AEFIs could arise. Therefore, clinicians should remain vigilant to worrisome signs and symptoms following COVID-19 vaccination. Hereon, we summarize some examples of rarely reported disorders that developed after immunization against COVID-19.

In the first place, a 51-year-old man with multiple comorbidities was being treated with clozapine for schizoaffective disorder. After receiving the BNT162b2 vaccine, he presented with delirium, normal pressure hydrocephalus, and a two-fold increase in blood clozapine levels. This adverse reaction was attributed to inflammation-related CYP1A2 (i.e. the cytochrome enzyme responsible for clozapine metabolism) inhibition.<sup>87</sup> Several studies have reported a link between inflammation and elevated levels of clozapine.<sup>88</sup> In addition, inflammatory mediators are known to reduce CYP1A2 activity.<sup>89</sup> Inflammation has been proposed to block drug-metabolizing enzymes via three mechanisms: stimulation of transcriptional regulators, induction of nitric oxide-dependent proteasome proteolysis of enzymes, and epigenetic modifications resulting in lower gene expression.<sup>88</sup> However, the extent of the impact of inflammation on clozapine levels is not clear. Despite the temporality and biological plausibility of this observed effect following an mRNA-based vaccine, the patient's pre-existing conditions may have played a significant role.

Other authors reported a patient with delirium and fever without meningeal irritation or neurological focal signs, accompanied by moderate widespread slowing on the electroencephalogram (EEG) after receiving the first dose of the ChAdOx1-S vaccine.<sup>90</sup> Increased BBB permeability was detected by lumbar punctures showing

high levels of CSF protein. Initially, CSF and serum proinflammatory cytokines, together with serum C reactive protein, were elevated. Hence, an exaggerated innate immune response could have been involved in what the authors regard as a cytokine storm-associated encephalopathy. This condition has been linked to an immune effector cell-associated neurotoxicity syndrome in other circumstances, such as chimeric antigen receptor T-cell treatments, COVID-19 infection, and autoimmune diseases.<sup>90</sup>

New-onset neuropathies following COVID-19 immunization are rare. In a case report, a 57-year-old female complained of intense burning dysesthesias in the extremities 1 week after receiving the BNT162b2 vaccine. Skin punch biopsies confirmed multifocal small fiber neuropathy. Having excluded other possible etiologies for the disease, the vaccine remains as a possible trigger. Previous reports have also described small fiber neuropathy following other vaccines.<sup>91</sup> A hypersensitivity reaction to polyethylene glycol was considered a possible mechanism for the pathogenesis in this case.<sup>92</sup>

Finally, transverse myelitis (TM) is a rare immune spinal cord disorder often induced directly by infection or by autoimmune responses during or following an infection.<sup>93</sup> TM has been previously linked with systemic infections and vaccinations, as these can cause inflammation of the spinal cord. Other relevant etiologies include multiple sclerosis, autoimmune diseases and neuromyelitis optica spectrum disorder.

Although this disease remains rare after vaccination, some authors report cases of TM following COVID-19 vaccines after a proper exclusion of alternative causes, such as CNS infection or active SARS-CoV-2 infection.<sup>93,94</sup> Although more cases have been described in the literature, the lack of clinical information in many cases precludes adequate causality assessments.<sup>93</sup> During ChAdOx1-S clinical trials, three cases were reported among a 11,636 cohort: two in the ChAdOx1-S arm and one in the control group. However, two of these cases (one in the ChAdOx1-S group and one in the control group) were deemed unlikely to be related to the administered drug.<sup>95</sup> Nevertheless, the occurrence of TM cases has raised concern as it represents a very serious condition and

should be carefully evaluated, including the exclusion of compressive and noninflammatory causes of myelitis.

### Discussion, concluding remarks, and future perspectives

Throughout this review, we have summarized and discussed the scientific literature regarding neurological complications following COVID-19 vaccines. Immunization campaigns have successfully reduced mortality and morbidity due to COVID-19, proving to be an effective public health measure to battle the ongoing pandemic. Although acceptable vaccine safety was reported during clinical trials, public concern arose because of numerous reports of AEFIs that emerged around the globe. Henceforth, epidemiological studies were carried out, some of them showing that the risk of certain neurological AEFIs is not higher than the risk of neurological complications due to COVID-19 or than the basal risk of these conditions in the general population. This underpins vaccine safety and should encourage the continuation of immunization campaigns as needed. Despite several cases of these neurological AEFIs have been reported in the literature, the overall evidence does not support a true association in many cases. However, this issue remains yet unresolved and awaits further exploration. Meanwhile, clinicians should remain vigilant of early manifestations of potentially serious neurological AEFIs, so as to allow early diagnosis and treatment, thus reducing the probability of long-lasting sequelae or fatal outcomes.

While billions of people have been immunized against COVID-19 all over the world, only a small proportion of them develop neurological AEFIs. It is reasonable to hypothesize that genetic factors are responsible for an increased susceptibility to these neurological complications in a subset of individuals, while the vaccine acts as an environmental trigger. Genetic association studies and next-generation sequencing could help identify candidate genes for these complex traits. However, to the best of our knowledge, no studies have yet explored the genetic basis of these neurologic adverse reactions after COVID-19 vaccines.

Although rare, neurological complications following COVID-19 immunization should persist

as a subject of pharmacovigilance and of epidemiological and biomedical research. Once vaccines were authorized by several regulatory entities, each country developed policies that prioritized certain population groups (e.g. health-care workers, vulnerable age groups). Therefore, initial epidemiological studies were based on samples that might not accurately represent the entire population. Now that vaccines are massively available in most countries, larger epidemiological studies should be carried out and ongoing pharmacovigilance should be encouraged, aiming to eliminate potential sources of bias and provide the scientific community with more accurate frequency data for these neurological AEFIs.

Even though the precise pathophysiological mechanisms underlying neurological AEFIs mechanisms are not fully understood, these conditions can still be serious, life-threatening or fatal. Clinical data suggest that anti-PF4 antibodies are involved in the genesis of CVST after COVID-19 vaccines, similar to what occurs in HIT. However, how these antibodies are produced in response to the immunizing agents is not well understood. Currently, most of the evidence that has contributed to the elucidation of the mechanisms that might underlie neurological AEFIs comes from experimental studies focusing on the virus and not the vaccine itself. More experimental studies are required to increase our understanding of the potential link between vaccination and altered homeostasis in the nervous system.

Despite the pathophysiological similarities that were initially contemplated between HIT and VIT, some distinctions have been progressively unraveled. Compared with the typical HIT, anti-PF4/polyanion IgG titers were higher and platelet aggregation was less dependent on physiologic levels of heparin and less sensitive to inhibition with high-dose heparin in VIT patients.<sup>18</sup> However, the clinical implications of these differences are yet to be determined. Furthermore, considering the potential relevance of anti-PF4 antibodies in the pathophysiology of CVST, additional clinical research should clarify the significance of serological screening among populations at risk. More specifically, it is worth determining if the detection of anti-PF4 antibodies in patients with prothrombotic risk factors or in those with a history

of autoimmunity has a predictive value that would justify prophylactic measures.

## Declarations

### *Ethics approval and consent to participate*

Not applicable because this manuscript is a literature review and did not involve human participants, original human data, or human tissue.

### *Consent for publication*

Not applicable because this manuscript is a literature review and did not involve human participants, original human data, or human tissue.

### *Author contributions*

**Sara Eslait-Olaciregui:** Conceptualization; Data curation; Investigation; Visualization; Writing – original draft; Writing – review & editing.

**Kevin Llinás-Caballero:** Conceptualization; Investigation; Methodology; Supervision; Visualization; Writing – original draft; Writing – review & editing.

**David Patiño-Manjarrés:** Conceptualization; Data curation; Investigation; Visualization; Writing – original draft; Writing – review & editing.

**Thomas Urbina-Ariza:** Data curation; Investigation; Visualization; Writing – original draft; Writing – review & editing.

**Juan Fernando Cediél-Becerra:** Conceptualization; Supervision; Writing – review & editing.

**Camilo Alberto Domínguez-Domínguez:** Conceptualization; Supervision; Writing – review & editing.

### *Acknowledgements*

Not applicable.

### *Funding*

The authors disclosed receipt of the following financial support for the research, authorship, and/or publication of this article: This project was supported by Universidad del Rosario

### *Competing interests*

The authors declared no potential conflicts of interest with respect to the research, authorship, and/or publication of this article.

**Availability of data and materials**

Not applicable.

**ORCID iD**Camilo Alberto Domínguez-Domínguez   
<https://orcid.org/0000-0001-8319-8291>**References**

- Kayser V and Ramzan I. Vaccines and vaccination: history and emerging issues. *Hum Vaccin Immunother* 2021; 17: 5255–5268.
- Tregoning JS, Flight KE, Higham SL, *et al.* Progress of the COVID-19 vaccine effort: viruses, vaccines and variants versus efficacy, effectiveness and escape. *Nat Rev Immunol* 2021; 21: 626–636.
- Teijaro JR and Farber DL. COVID-19 vaccines: modes of immune activation and future challenges. *Nat Rev Immunol* 2021; 21: 195–197.
- García-Grimshaw M, Ceballos-Liceaga SE, Hernández-Vanegas LE, *et al.* Neurologic adverse events among 704,003 first-dose recipients of the BNT162b2 mRNA COVID-19 vaccine in Mexico: a nationwide descriptive study. *Clin Immunol* 2021; 229: 108786.
- Gee J, Marquez P, Su J, *et al.* First month of COVID-19 vaccine safety monitoring – United States, December 14, 2020–January 13, 2021. *MMWR Morb Mortal Wkly Rep* 2021; 70: 283–288.
- Shay DK, Gee J, Su JR, *et al.* Safety monitoring of the Janssen (Johnson & Johnson) COVID-19 vaccine – United States, March–April 2021. *MMWR Morb Mortal Wkly Rep* 2021; 70: 680–684.
- McCrae KR. Thrombotic thrombocytopenia due to SARS-CoV-2 vaccination. *Cleve Clin J Med*. Epub ahead of print 6 May 2021. DOI: 10.3949/ccjm.88a.ccc078.
- Greinacher A, Thiele T, Warkentin TE, *et al.* Thrombotic thrombocytopenia after ChAdOx1 nCov-19 vaccination. *N Engl J Med* 2021; 384: 2092–2101.
- Kowarz E, Krutzke L, Külpe M, *et al.* Vaccine-induced COVID-19 mimicry syndrome. *Elife* 2022; 11: e74974.
- Muir K-L, Kallam A, Koepsell SA, *et al.* Thrombotic thrombocytopenia after Ad26.COV2.S vaccination. *N Engl J Med* 2021; 384: 1964–1965.
- de Michele M, Iacobucci M, Chistolini A, *et al.* Malignant cerebral infarction after ChAdOx1 nCov-19 vaccination: a catastrophic variant of vaccine-induced immune thrombotic thrombocytopenia. *Nat Commun* 2021; 12: 4663.
- Pottegård A, Lund LC, Karlstad Ø, *et al.* Arterial events, venous thromboembolism, thrombocytopenia, and bleeding after vaccination with Oxford-AstraZeneca ChAdOx1-S in Denmark and Norway: population based cohort study. *BMJ* 2021; 373: n1114.
- World Health Organization. Causality assessment of an adverse event following immunization (AEFI) user manual for the revised WHO classification, <https://www.who.int/publications/item/9789241516990>
- Dias L, Soares-Dos-Reis R, Meira J, *et al.* Cerebral venous thrombosis after BNT162b2 mRNA SARS-CoV-2 vaccine. *J Stroke Cerebrovasc Dis* 2021; 30: 105906.
- Ezeh E, Katabi A and Khawaja I. Iron deficiency anemia as a rare risk factor for recurrent pulmonary embolism and deep vein thrombosis. *Cureus* 2021; 13: e13721.
- Gialeraki A, Valsami S, Pittaras T, *et al.* Oral contraceptives and HRT risk of thrombosis. *Clin Appl Thromb Hemost* 2018; 24: 217–225.
- Taquet M, Husain M, Geddes JR, *et al.* Cerebral venous thrombosis and portal vein thrombosis: a retrospective cohort study of 537,913 COVID-19 cases. *Eclinicalmedicine* 2021; 39: 101061.
- Schultz NH, Sørvoll IH, Michelsen AE, *et al.* Thrombosis and thrombocytopenia after ChAdOx1 nCoV-19 vaccination. *N Engl J Med* 2021; 384: 2124–2130.
- Wolf ME, Luz B, Niehaus L, *et al.* Thrombocytopenia and intracranial venous sinus thrombosis after ‘COVID-19 vaccine AstraZeneca’ exposure. *J Clin Med* 2021; 10: 1599.
- Sheikh S. Thrombotic thrombocytopenia and central venous sinus thrombosis post – COVID-19 vaccination and its treatment with heparin alternatives. *J Coll Physicians Surg Pak* 2021; 31: 149.
- Jamme M, Mosnino E, Hayon J, *et al.* Fatal cerebral venous sinus thrombosis after COVID-19 vaccination. *Intensive Care Med* 2021; 47: 790–791.
- Zakaria Z, Sapiai NA and Ghani ARI. Cerebral venous sinus thrombosis 2 weeks after the first dose of mRNA SARS-CoV-2 vaccine. *Acta Neurochir* 2021; 163: 2359–2362.

23. See I, Su JR, Lale A, *et al.* US case reports of cerebral venous sinus thrombosis with thrombocytopenia after Ad26.COV2.S vaccination, March 2 to April 21, 2021. *JAMA* 2021; 325: 2448.
24. Sørvoll IH, Horvei KD, Ernstsén SL, *et al.* An observational study to identify the prevalence of thrombocytopenia and anti-PF4/polyanion antibodies in Norwegian health care workers after COVID-19 vaccination. *J Thromb Haemost* 2021; 19: 1813–1818.
25. Mehta PR, Apap Mangion S, Bengner M, *et al.* Cerebral venous sinus thrombosis and thrombocytopenia after COVID-19 vaccination – a report of two UK cases. *Brain Behav Immun* 2021; 95: 514–517.
26. Fanni D, Saba L, Demontis R, *et al.* Vaccine-induced severe thrombotic thrombocytopenia following COVID-19 vaccination: a report of an autoptic case and review of the literature. *Eur Rev Med Pharmacol Sci* 2021; 25: 5063–5069.
27. Castelli GP, Pognani C, Sozzi C, *et al.* Cerebral venous sinus thrombosis associated with thrombocytopenia post-vaccination for COVID-19. *Crit Care* 2021; 25: 137.
28. Franchini M, Testa S, Pezzo M, *et al.* Cerebral venous thrombosis and thrombocytopenia post-COVID-19 vaccination. *Thromb Res* 2021; 202: 182–183.
29. Aladdin Y, Algahtani H and Shirah B. Vaccine-induced immune thrombotic thrombocytopenia with disseminated intravascular coagulation and death following the ChAdOx1 nCoV-19 vaccine. *J Stroke Cerebrovasc Dis* 2021; 30: 105938.
30. Scully M, Singh D, Lown R, *et al.* Pathologic antibodies to platelet factor 4 after ChAdOx1 nCoV-19 vaccination. *N Engl J Med* 2021; 384: 2202–2211.
31. Abou-Ismaïl MY, Diamond A, Kapoor S, *et al.* The hypercoagulable state in COVID-19: incidence, pathophysiology, and management. *Thromb Res* 2020; 194: 101–115.
32. Bano F, Badugama B and Chandra D. Thrombosis and thrombocytopenia after ChAdOx1 nCoV-19 vaccination: a single UK centre experience. *BMJ Case Rep* 2021; 14: e243894.
33. Li X, Weber NC, Cohn DM, *et al.* Effects of hyperglycemia and diabetes mellitus on coagulation and hemostasis. *J Clin Med* 2021; 10: 2419.
34. Huang D, Refaat M, Mohammedi K, *et al.* Macrovascular complications in patients with diabetes and prediabetes. *Biomed Res Int* 2017; 2017: 1–9.
35. Bayas A, Menacher M, Christ M, *et al.* Bilateral superior ophthalmic vein thrombosis, ischaemic stroke, and immune thrombocytopenia after ChAdOx1 nCoV-19 vaccination. *Lancet* 2021; 397: e11.
36. Warkentin TE. High-dose intravenous immunoglobulin for the treatment and prevention of heparin-induced thrombocytopenia: a review. *Expert Rev Hematol* 2019; 12: 685–698.
37. Blauenfeldt RA, Kristensen SR, Ernstsén SL, *et al.* Thrombocytopenia with acute ischemic stroke and bleeding in a patient newly vaccinated with an adenoviral vector-based COVID-19 vaccine. *J Thromb Haemost* 2021; 19: 1771–1775.
38. Huynh A, Kelton JG, Arnold DM, *et al.* Antibody epitopes in vaccine-induced immune thrombotic thrombocytopenia. *Nature* 2021; 596: 565–569.
39. George R, Bhatt A, Narayani J, *et al.* Enhanced P-selectin expression on platelet—a marker of platelet activation, in young patients with angiographically proven coronary artery disease. *Mol Cell Biochem* 2016; 419: 125–133.
40. Althaus K, Möller P, Uzun G, *et al.* Antibody-mediated procoagulant platelets in SARS-CoV-2-vaccination associated immune thrombotic thrombocytopenia. *Haematologica* 2021; 106: 2170–2179.
41. Merten M and Thiagarajan P. P-selectin in arterial thrombosis. *Z Kardiol* 2004; 93: 855–863.
42. Tiede A, Sachs UJ, Czwalińska A, *et al.* Prothrombotic immune thrombocytopenia after COVID-19 vaccination. *Blood* 2021; 138: 350–353.
43. Buzhdygan TP, DeOre BJ, Baldwin-Leclair A, *et al.* The SARS-CoV-2 spike protein alters barrier function in 2D static and 3D microfluidic in-vitro models of the human blood–brain barrier. *Neurobiol Dis* 2020; 146: 105131.
44. Zhang S, Liu Y, Wang X, *et al.* SARS-CoV-2 binds platelet ACE2 to enhance thrombosis in COVID-19. *J Hematol Oncol* 2020; 13: 120.
45. Corbett KS, Flynn B, Foulds KE, *et al.* Evaluation of the mRNA-1273 vaccine against SARS-CoV-2 in nonhuman primates. *N Engl J Med* 2020; 383: 1544–1555.
46. Vogel AB, Kanevsky I, Che Y, *et al.* BNT162b vaccines protect rhesus macaques from SARS-CoV-2. *Nature* 2021; 592: 283–289.

47. Owens AP III and Mackman N. Tissue factor and thrombosis: the clot starts here. *Thromb Haemost* 2010; 104: 432–439.
48. Rempe RG, Hartz AMS and Bauer B. Matrix metalloproteinases in the brain and blood–brain barrier: versatile breakers and makers. *J Cereb Blood Flow Metab* 2016; 36: 1481–1507.
49. López-Mena D, García-Grimshaw M, Saldivar-Dávila S, *et al.* Stroke among SARS-CoV-2 vaccine recipients in Mexico. *Neurology* 2022; 98: e1933–e1941.
50. Cascio Rizzo A, Giussani G and Agostoni EC. Ischemic stroke and vaccine-induced immune thrombotic thrombocytopenia following COVID-19 vaccine: a case report with systematic review of the literature. *Cerebrovasc Dis* 2022; 51: 722–734.
51. Pavord S, Scully M, Hunt BJ, *et al.* Clinical features of vaccine-induced immune thrombocytopenia and thrombosis. *N Engl J Med* 2021; 385: 1680–1689.
52. Stefanou M-I, Palaiodimou L, Aguiar de Sousa D, *et al.* Acute arterial ischemic stroke following COVID-19 vaccination. *Neurology* 2022; 99: e1465–e1474.
53. Hidayat R, Diafiri D, Zairinal RA, *et al.* Acute ischaemic stroke incidence after coronavirus vaccine in Indonesia: case series. *Curr Neurovasc Res* 2021; 18: 360–363.
54. Wills A, Swallow G, Kirkman MA, *et al.* Arterial and venous thrombotic stroke after ChAdOx1 nCoV-19 vaccine. *Clin Med* 2022; 22: 184–186.
55. Kenda J, Lovrič D, Škerget M, *et al.* Treatment of ChAdOx1 nCoV-19 vaccine-induced immune thrombotic thrombocytopenia related acute ischemic stroke. *J Stroke Cerebrovasc Dis* 2021; 30: 106072.
56. Botton J, Jabagi MJ, Bertrand M, *et al.* Risk for myocardial infarction, stroke, and pulmonary embolism following COVID-19 vaccines in adults younger than 75 years in France. *Ann Intern Med* 2022; 175: 1250–1257.
57. Rahmig J, Altarsha E, Siepmann T, *et al.* Acute ischemic stroke in the context of SARS-CoV-2 vaccination: a systematic review. *Neuropsychiatr Dis Treat* 2022; 18: 1907–1916.
58. Silverman IE, Restrepo L and Mathews GC. Poststroke seizures. *Arch Neurol* 2002; 59: 195.
59. Belov Kirdajova D, Kriska J, Tureckova J, *et al.* Ischemia-triggered glutamate excitotoxicity from the perspective of glial cells. *Front Cell Neurosci* 2020; 14: 51.
60. Kalita J, Chandra S and Misra UK. Significance of seizure in cerebral venous sinus thrombosis. *Seizure* 2012; 21: 639–642.
61. Uluduz D, Midi I, Duman T, *et al.* Epileptic seizures in cerebral venous sinus thrombosis: subgroup analysis of VENOST study. *Seizure* 2020; 78: 113–117.
62. Aladdin Y and Shirah B. New-onset refractory status epilepticus following the ChAdOx1 nCoV-19 vaccine. *J Neuroimmunol* 2021; 357: 577629.
63. Marchetti L and Engelhardt B. Immune cell trafficking across the blood-brain barrier in the absence and presence of neuroinflammation. *Vasc Biol* 2020; 2: H1–H18.
64. Xu D, Miller SD and Koh S. Immune mechanisms in epileptogenesis. *Front Cell Neurosci* 2013; 7: 195.
65. Nikbakht F, Mohammadkhanizadeh A and Mohammadi E. How does the COVID-19 cause seizure and epilepsy in patients? The potential mechanisms. *Mult Scler Relat Disord* 2020; 46: 102535.
66. van den Berg B, Walgaard C, Drenthen J, *et al.* Guillain-Barré syndrome: pathogenesis, diagnosis, treatment and prognosis. *Nat Rev Neurol* 2014; 10: 469–482.
67. Patel SU, Khurram R, Lakhani A, *et al.* Guillain-Barre syndrome following the first dose of the chimpanzee adenovirus-vectored COVID-19 vaccine, ChAdOx1. *BMJ Case Rep* 2021; 14: e242956.
68. Medicines Healthcare products Regulatory Agency. Case series drug analysis print name: COVID-19 vaccine AstraZeneca analysis print, 2022, [https://assets.publishing.service.gov.uk/government/uploads/system/uploads/attachment\\_data/file/997110/FOI\\_21-435\\_PDF\\_Attachment\\_2.pdf](https://assets.publishing.service.gov.uk/government/uploads/system/uploads/attachment_data/file/997110/FOI_21-435_PDF_Attachment_2.pdf)
69. Maramattom BV, Krishnan P, Paul R, *et al.* Guillain-Barré syndrome following ChAdOx1-S/nCoV-19 vaccine. *Ann Neurol* 2021; 90: 312–314.
70. Hanson KE, Goddard K, Lewis N, *et al.* Incidence of Guillain-Barré syndrome after COVID-19 vaccination in the vaccine safety datalink. *JAMA Netw Open* 2022; 5: e228879.
71. Woo EJ, Mba-Jonas A, Dimova RB, *et al.* Association of receipt of the Ad26.COV2.S COVID-19 vaccine with presumptive Guillain-Barré syndrome, February–July 2021. *JAMA* 2021; 326: 1606.

72. García-Grimshaw M, Galnares-Olalde JA, Bello-Chavolla OY, *et al.* Incidence of Guillain–Barré syndrome following SARS-CoV2 immunization: analysis of a nationwide registry of recipients of 81 million doses of seven vaccines. *Eur J Neurol* 2022; 29: 3368–3379.
73. Kim JE, Park J, Min YG, *et al.* Associations of Guillain–Barré syndrome with coronavirus disease 2019 vaccination: disproportionality analysis using the World Health Organization pharmacovigilance database. *J Peripher Nerv Syst* 2022; 27: 206–214.
74. Chun JY, Park S, Jung J, *et al.* Guillain–Barré syndrome after vaccination against COVID-19. *Lancet Neurol* 2022; 21: 117–119.
75. Allen CM, Ramsamy S, Tarr AW, *et al.* Guillain–Barré syndrome variant occurring after SARS-CoV-2 vaccination. *Ann Neurol* 2021; 90: 315–318.
76. Babazadeh A, Mohseni Afshar Z, Javanian M, *et al.* Influenza vaccination and Guillain–Barré syndrome: reality or fear. *J Transl Int Med* 2019; 7: 137–142.
77. Tutar NK, Eyigürbüz T, Yildirim Z, *et al.* A variant of Guillain–Barre syndrome after SARS-CoV-2 vaccination: AMSAN. *Idegyogy Sz* 2021; 74: 286–288.
78. Nelson KE. Invited commentary: influenza vaccine and Guillain–Barre syndrome—is there a risk? *Am J Epidemiol* 2012; 175: 1129–1132.
79. Baugh RF, Basura GJ, Ishii LE, *et al.* Clinical practice guideline. *Otolaryngol Head Neck Surg* 2013; 149: S1–S27.
80. US Food and Drug Administration. Vaccines and related biological products advisory committee December 10, 2020 meeting briefing document – FDA, 2020, <https://www.fda.gov/advisory-committees/advisory-committee-calendar/vaccines-and-related-biological-products-advisory-committee-december-10-2020-meeting-announcement>
81. Baden LR, el Sahly HM, Essink B, *et al.* Efficacy and safety of the mRNA-1273 SARS-CoV-2 vaccine. *N Engl J Med* 2021; 384: 403–416.
82. Shemer A, Pras E, Einan-Lifshitz A, *et al.* Association of COVID-19 vaccination and facial nerve palsy. *JAMA Otolaryngol Head Neck Surg* 2021; 147: 739.
83. Walker NR, Mistry RK and Mazzoni T. *Facial nerve palsy*. Treasure Island, FL: StatPearls Publishing, 2022.
84. Shemer A, Pras E and Hecht I. Peripheral facial nerve palsy following BNT162b2 (COVID-19) vaccination. *Isr Med Assoc J* 2021; 23: 143–144.
85. Burrows A, Bartholomew T, Rudd J, *et al.* Sequential contralateral facial nerve palsies following COVID-19 vaccination first and second doses. *BMJ Case Rep* 2021; 14: e243829.
86. Wan EYF, Chui CSL, Lai FTT, *et al.* Bell’s palsy following vaccination with mRNA (BNT162b2) and inactivated (CoronaVac) SARS-CoV-2 vaccines: a case series and nested case-control study. *Lancet Infect Dis* 2022; 22: 64–72.
87. Thompson D, Delorme CM, White RF, *et al.* Elevated clozapine levels and toxic effects after SARS-CoV-2 vaccination. *J Psychiatry Neurosci* 2021; 46: E210–E211.
88. Stanke-Labesque F, Gautier-Veyret E, Chhun S, *et al.* Inflammation is a major regulator of drug metabolizing enzymes and transporters: consequences for the personalization of drug treatment. *Pharmacol Ther* 2020; 215: 107627.
89. Dickmann LJ, Patel SK, Rock DA, *et al.* Effects of interleukin-6 (IL-6) and an anti-IL-6 monoclonal antibody on drug-metabolizing enzymes in human hepatocyte culture. *Drug Metab Dispos* 2011; 39: 1415–1422.
90. Baldelli L, Amore G, Montini A, *et al.* Hyperacute reversible encephalopathy related to cytokine storm following COVID-19 vaccine. *J Neuroimmunol* 2021; 358: 577661.
91. Kafaie J, Kim M and Krause E. Small fiber neuropathy following vaccination. *J Clin Neuromuscul Dis* 2016; 18: 37–40.
92. Waheed W, Carey ME, Tandan SR, *et al.* Post COVID-19 vaccine small fiber neuropathy. *Muscle Nerve* 2021; 64: E1–E2.
93. Pagenkopf C and Südmeyer M. A case of longitudinally extensive transverse myelitis following vaccination against Covid-19. *J Neuroimmunol* 2021; 358: 577606.
94. Hsiao Y-T, Tsai M-J, Chen Y-H, *et al.* Acute transverse myelitis after COVID-19 vaccination. *Medicina* 2021; 57: 1010.
95. Voysey M, Clemens SAC, Madhi SA, *et al.* Safety and efficacy of the ChAdOx1 nCoV-19 vaccine (AZD1222) against SARS-CoV-2: an interim analysis of four randomised controlled trials in Brazil, South Africa, and the UK. *Lancet* 2021; 397: 99–111.